Chapter 1

Oncoplastic Breast Surgery

Shariful Islam* and Vijay Naraynsingh

Department of Clinical Surgical Sciences, University of the West Indies, St. Augustine, Trinidad & Tobago

***Corresponding Author:** Shariful Islam, Department of Clinical Surgical Sciences, University of the West Indies, St. Augustine, Trinidad & Tobago, Email: shar_islam7@hotmail.com

Published **December 10, 2017**

Introduction

Breast-conservation surgery (BCS) has become the standard of care for early breast cancer, with excellent survival rates. In fact, the 5-year survival of BCS with radiation is not statistically different when compared to mastectomy alone in patients with Stage I or II breast cancer [1]. However, the focus of BCS has now shifted to cosmetic outcome, quality of life and patient satisfaction. Nonetheless, excision of certain tumours still presents a considerable challenge. Oncoplastic breast surgery has enabled surgeons to remove a greater volume of tissue successfully, and thus reduces mastectomy and re-excision rates. It also has reduced the degree of surgical trauma, and is capable of preserving the cosmesis of the breast as well as improving quality of life.

Although most BCS defects can be managed with primary closure, the aesthetic outcome may be unpredictable. Oncoplastic reconstruction may begin immediately at the time of BCS or delayed-immediate in weeks or delayed, months to years afterwards. With immediate reconstruction, the surgical process is smooth, since both procedures can be done in one operative setting.

Additionally, it permits wider excision of the tumour with a superior mean volume of the specimen and potentially reduces the incidence of margin involvement. The oncoplastic techniques are related to volume-displace-

ment or replacement procedures, including local flaps, latissimus dorsi myo-cutaneous flap and reduction mammoplasty / mastopexy. Regardless of the fact that there is no consensus on the best approach, the criteria are determined by the surgeon's experience and the size of the defect in relation to the size of the remaining breast. The main advantages of the technique utilized should include reproducibility, low interference with the oncologic treatment, and long-term results. Surgical planning should take into consideration the patient's preference and chiefly address individual reconstructive requirements, thereby enabling each patient to receive an individual "custom-made" reconstruction.

Historical Background

Breast cancer is the commonest cause of death from cancer among women worldwide.

Breast conservation surgery with adjuvant radiotherapy is now widely accepted as a treatment modality for women with early stage breast cancer. Prospective, randomised trials, with 20 years reported outcome in some studies, have demonstrated no difference in breast cancer mortality and overall survival when compared to women treated with mastectomy [1-3]. The success of BCS is based around the principles of complete removal of the tumour with adequate surgical margins, whilst preserving the natural shape and appearance of the breast. Historically, breast conservation has not always achieved a good

cosmetic result, which has had the resultant sequelae of negative patient-reported outcome scores, for example body image and quality of life. The deformities caused by poorly planned BCS are often severe and difficult to manage, with high levels of complications and dissatisfaction [4]. Oncoplastic breast conserving surgical techniques have emerged over recent years, facilitating the achievement of better cosmetic results whilst maintaining good oncological principles.

A new term Onco-Aesthetic surgery has recently been coined by Carmichael et al [5] for the modern management of breast cancer.

Historical evolution of Breast cancer Surgery
William Halsted popularized radical mastectomy in 1894
Modified Radical Mastectomy (MRM)
Total (Simple) Mastectomy
More recently, Skin sparing mastectomy (SSM)
Nipple sparing mastectomy (NSM)
Breast Conserving Therapy (BCT)- includes both BCS and breast radiotherapy
Oncoplastic breast surgery
Onco-Aesthetic breast surgery

Definition

The term "oncoplastic" is a Greek-derived word which literally means "moulding of tumour". It first appeared in the literature in 1996 [6]. Werner Audretsch, considered by some as the father of oncoplastic surgery, described the technique of reconstructing a partial mastectomy defect

in 1998 as a further refinement of breast conservation, avoiding mastectomy [7,8]. Oncoplastic surgery does not refer to any given procedure; instead it describes a surgical mindset in the approach of a patient facing various types of breast surgery. Modern oncoplastic breast surgery combines the principles of oncologic and plastic surgery techniques, to obtain oncologically sound and aesthetically pleasing results. It creates the avenue of minimalistic breast surgery.

Patient Selection and Counseling

The decision-making process is very complex, and requires adequate counseling. Cosmesis is now very important. It helps patient to recover psychologically, as well as physically. It is well recognized that oncoplastic surgery can improve surgical outcomes in a safe and effective manner as long as patient selection is appropriate. It is for this reason that a multi-disciplinary approach to the preoperative work-up is key to the practice of oncoplastic surgery.

A comprehensive history and physical examination, complete personal/family medical history, and evaluation of additional risk factors, such as hormone replacement therapy, history of radiation treatment for Hodgkin's disease, etc., general medical condition, smoking history, history of previous breast surgery, biopsies, implants (including size / type) are all of paramount importance before deciding on oncoplastic surgery.

Similarly, a review of all breast imaging (mammography, ultrasound, MRI) before surgery & BRCA testing (if indicated) are important in the decision-making process. However, the most important factor before any oncoplastic surgery is to ascertain patient desire, with regards to breast shape, size and symmetry.

Pre-operative and successive post-operative views should be taken for counseling all patients undergoing oncoplastic breast surgery, with a standard set of views acquired in a studio setting. There should be a full and tiered consent process for this, which must be followed with each patient [9].

Before embarking on oncoplastic surgery, a careful assessment must be made about the available support systems, including adequately trained personnel, facilities for proper investigation, reputable and timely pathology, radiation & chemotherapy services, with adequate social and psychological support system.

The following points must be considered before proceeding with oncoplastic breast surgery:

- Volume of tissue to be excised
- Tumour location
- Breast size and glandular density
- Patient related risk factors, particularly smoking, obesity, diabetes, previous surgery
- Adjuvant therapies

However, the decision is usually determined by the surgeon's preferences and the size of the defect in relation to the size of the remaining breast. In fact, it is very important to identify trends in all types of breast defects on the basis of the initial breast volume, the extent and location of glandular tissue resection and the remaining available breast tissue.

Excision Volume of the Breast

The excision volume is the single best predictive factor for breast deformity [10]. Bulstrode et al, reported that excision of more than 20% of breast volume is associated with a substantial risk of deformity [11]. Tumour location is another important consideration. Excision of tumours from the upper inner quadrant and lower pole of the breast are at particular risk of leaving a severe deformity. For example, excision of tumours from the lower pole carries the risk of a "bird's beak" deformity [12].

Size of the breast and Oncoplastic Technique

Selection of appropriate oncoplastic techniques for each patient varies based on the size of their breast.

For Smaller Breast

Smaller breasts require different methods of reconstruction, and with a large-volume tumour resection, the

recruitment of local flaps is required. In many cases, patients with small breasts often choose mastectomy rather than breast conservation. These patients frequently make excellent candidates for using creative surgical techniques for mastectomy, and they tend to share some common factors. Often these patients present at an early stage of disease, but the tumor may require a relatively large excision in comparison to the volume of existing breast tissue.

These patients may also present at a young age and they frequently lead active lifestyles. In addition, they may fear or truly be faced with an increased risk for cancer recurrence due to several factors, such as histologic subtype, family history of breast cancer, extended longevity, and / or other factors. Consequently, many of these patients seek mastectomy, and often they desire immediate reconstruction. In this setting, skin-sparing mastectomy with immediate implant reconstruction can be the ideal solution for an aesthetically pleasing appearance of the breast. It is usually done as a staged procedure.

For Larger Breast

Patients with large breasts afford oncoplastic surgeons more options for surgical creativity. The medium size breast groups also offer the oncoplastic surgeons a variety surgical approach depending on the location of primary tumour.

Contraindications for Breast Conservation

Breast conservation is contraindicated (Association of Breast Surgery at BASO, et al. 2007) in the following conditions [13]:

- When clear margins cannot be assured without performing a mastectomy
- In patients with T4 tumours
- In the setting of extensive multi-centric disease
- Extensive malignant micro-calcifications
- Inflammatory breast cancer

For locally advanced breast tumors, oncoplastic breast surgery has the same results than conventional breast conserving surgery. Costa Vieiraa et al in a matched case controlled study of 78 locally advanced breast cancer patients noted that OS is a safe procedure for LABC, offering the similar oncologic results observed in patients submitted to classic BCS [14].

Principles of Oncoplastic Resection

- Make sure that adequate vascular supply maintained
- Move skin with nipple areolar complex on underlying breast

- Move breast against muscle
- Breast segment to be moved to a different location
- Pull nipple areolar complex in appropriate direction (Superior or inferior pedicle based)

Selections of the Levels of Oncoplastic Resection

- Level 1- (Dual plane undermining)

Patients tolerating dual plane undermining (BIRADS 3& 4)

o Lesser volume loss

o Level 2- (Dermoglandular flap-single plane undermining)

- For breast not tolerating dual plane undermining (BIRADS 1 & 2)

o For larger volume resection

o For patients requesting reduction at the same time

Selection of Technique

Clough et al. have described the use of a bi-level classification system in selecting the most appropriate technique of oncoplastic breast conservation surgery. If less than 20% of the breast volume is to be excised, then they advocate the use of a level I procedure, encompassing the following steps:

- Skin incision
- De-epithelisation of the peri-areolar skin
- Full thickness glandular excision
- Skin undermining following the mastectomy plane, to facilitate resection of tumour as well as glandular redistribution once the tumour has been removed
- Nipple areola complex (NAC) undermining
- Glandular defect closure with tissue re-approximation; if required, an area in the shape of a crescent bordering the areola is de-epithelised, and the NAC repositioned.

Figure 1: Preoperative marking of the right breast Figure: Peri-areolar strip of epidermis are removed and incision made along the marked line 1-2 cm away from the lump in all direction.

Figure 2: Breast lump with overlying dissected down to the Pectoralis major muscle and Mobilization of breast plate Figure: Defect closed in layers with reconstruction of the NAC reconstructed.

Figure 3: Final appearance after skin closure.

However, if more than 20% of the breast volume needs to be excised, a more complex procedure is deemed necessary at this stage which required which further specialized training in oncoplastic breast surgery. Patients should be counseled thoroughly in the pre-operative setting, regarding resultant scars using oncoplastic techniques and the potential requirement for symmetrisation procedures. These techniques can be broadly categorised into volume displacement and volume replacement techniques, and contra lateral breast surgery. According to Kronowitz et al, the most commonly employed techniques are mastopexy, reduction mammoplasty, local and distant flaps [15].

Volume Displacement

Volume displacement involves the principle of mobilising local glandular or dermo-glandular flaps and transposing them into the resection defect. This employs predominantly a mammoplasty technique, resulting in a net loss of breast volume, and gives rise to the potential requirement for contralateral symmetrisation procedures. Type I procedures, as described by Clough et al, also employ the use of glandular remodelling as part of volume displacement, but with lesser volume excisions than type II procedures.

There are a range of mammoplasty techniques which can be utilised. The most important factor is the tumour locations which will influence not only the selection of

appropriate skin incision but also the excision pattern, and where appropriate, pedicle utilisation for nipple re-positioning. A range of approaches have been advocated, and generally divide the breast into quadrants or "zones" for planning the surgical approach [16, 17]. Schematically rotating the nipple areola pedicle opposite to the site of tumour excision allows the application of these techniques for a variety of tumour locations [16].

The most commonly used incisions are:

- Wise-pattern type with the Superior and Inferior pedicle mammoplasty
- Batwing mastopexy
- Round-block or Benelli technique
- Modified round-block technique
- Grissotti flaps technique
- Vertical reduction-mammoplasty or Lejour type
- The Tennis racket method
- The Purse string suture
- The Parallelogram mastopexy

Diagrams of Different Oncoplastic Techniques

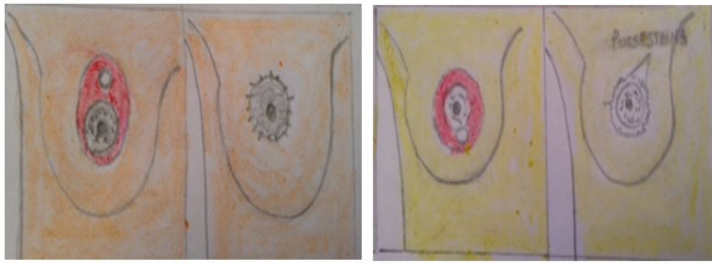

Figure 4: Round block/ Peri-areolar (purse string) mammoplasty.

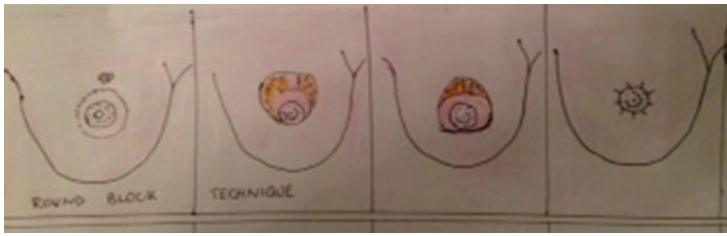

Figure 5: Modified round block technique.

Figure 6: L- plasty.

Figure 7: J – plasty.

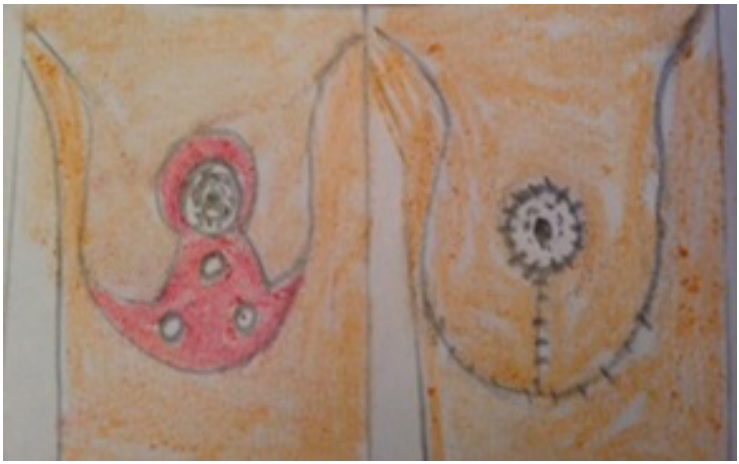

Figure 8: Inverted T mammoplasty.



Figure 9: Inferior pedicle mammoplasty.

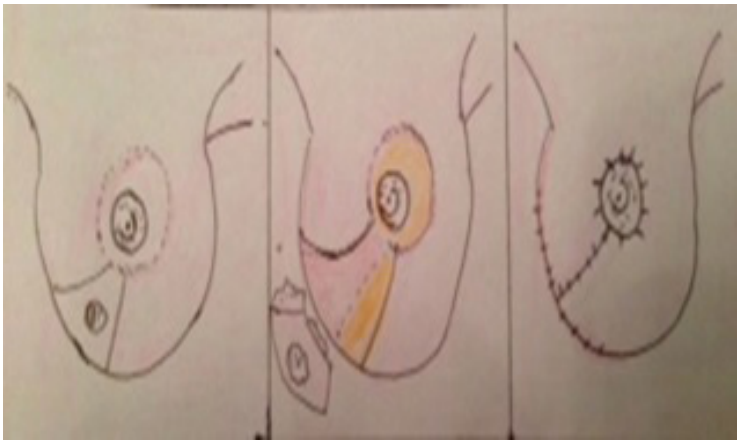

Figure 10: Inverted V- plasty.

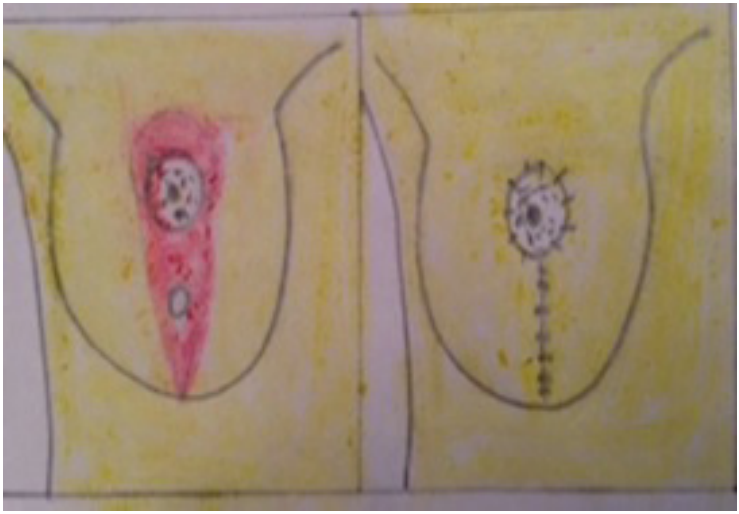

Figure 11: Vertical.

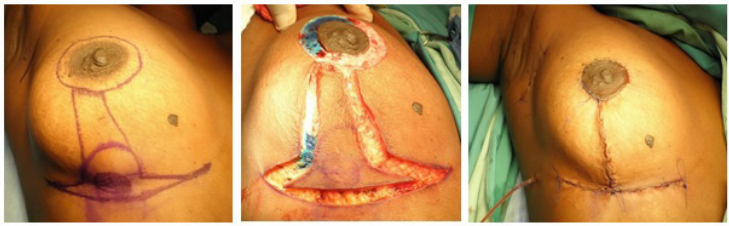

Figure 12: Inverted T mammoplasty.

Figure 13: Inverted T mammoplasty.

Figure 14: Batwing /omega mammoplasty.

Figure 15: Batwing /omega mammoplasty.

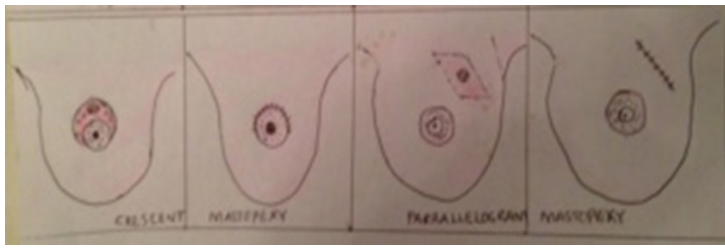

Figure 16: Crescent mastopexy and Parallelogram mammoplasty.

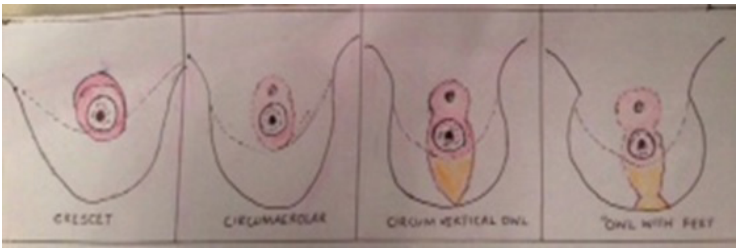

Figure 17: Crescent / Circum-areolar / Circum-vertical (owl)/ Owl with feet mammoplasty.

Figure 18: Crescent mammaplasty / Inferior mammary fold plasty.

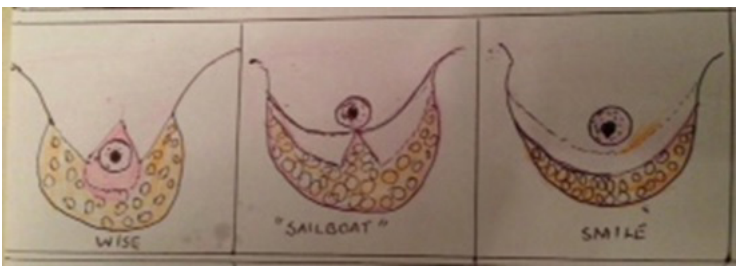

Figure 19: Wise pattern / sailboat pattern / Smile mammoplasty.

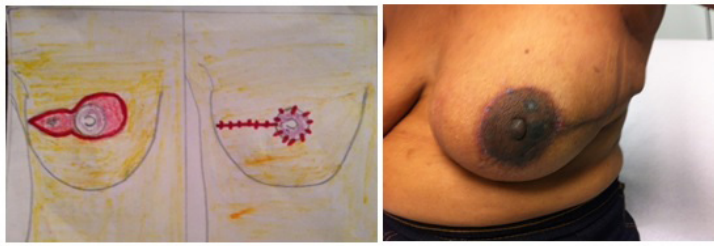

Figure 20: Lateral mammaplasty.

Figure 21: Lateral mammaplasty.

Figure 22: Medial mammaplasty.

Figure 23: Medial mammaplasty.

Figure 24: Grissotti flaps technique.

Summary of Quadrant per Quadrant Oncoplastic Procedures

Clock Position	**Oncoplastic Techniques**
12 o'clock Upper pole	• Inferior pedicle mammaplasty (wise pattern) • Round block • Crescent type
1-2 o'clock Upper outer quadrant (UOQ)	• Tennis Racquet • Parallelogram • Radial scar
9-11 o'clock Upper Inner quadrant (UIQ)	• Batwings mammaplasty • Rotation flap
5-7 O'clock- Lower pole	Superior pedicle mammaplasty • Wise pattern • Vertical reduction
7-8 o'clock Lower inner quadrant (LIQ)	• Superior pedicle mammaplasty -Wise pattern - Vertical reduction • Repair rotated 7-8 o'clock (J scar) • V scar
4-5 o'clock Lower outer quadrant (LOQ)	• Superior pedicle mammaplasty -Wise pattern -Vertical reduction • Repair rotated 4-5 o'clock (J scar)
Central sub-areolar	• Grissotti • Superior pedicle Grissotti type • Vertical scar with NAC resection • Inverted T

Volume Replacement

Using these techniques, autologous tissue is harvested and transferred from a remote site to the resection defect. This can be performed as either a pedicle or a free flap. Traditionally, this has involved the use of latissimus dorsi flaps [18]. However, newer techniques are evolving, for example, lateral intercostal artery perforator flaps which are based on intercostal perforators arising from the costal groove [19]. These confer an advantage over thoracodorsal artery perforator flaps (TDAP) and latissimus dorsi mini-flaps, by enabling preservation of the thoracodorsal pedicle should a mastectomy and latissimus dorsi flap breast re-construction be required in the future.

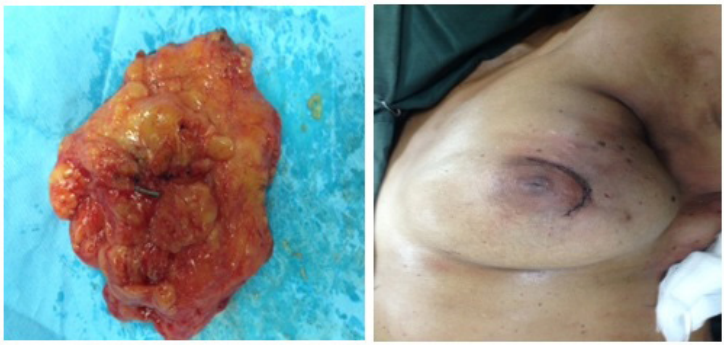

Figure 25: Breast cancer excised from the left UOQ and the volume is replaced with LD flaps through the same axillary incision.

Recently Naraynsingh et al, (2009) described a unique technique of filling the defects left after BCS. In this series

the author used a latissimus dorsi myoadipose flap rather than traditional myocutaneous flap, through the same axillary incision used for the axillary dissection. Both communication branches of the lateral thoracic artery and thoracodorsal pedicle were preserved, thus providing a dual blood supply to the flap. The unique advantages of this technique include avoidance of a long scar on the back and the need to change the patient position intraoperatively for the posterior dissection, and lack of a contour defect in the back. Additionally, a thick pad of fat, along with the muscle, can triple or quadruple the bulk for filling the breast defect. This permits generous, uncompromised wide clearance of the tumour, with minimal or no deformity. Since the latissimus dorsi myoadipose flap has a dual blood supply, it is quite robust and can tolerate the usual radiotherapy which follows wide local excision of a breast carcinoma. The author concluded that immediate breast reconstruction following segmentectomy, by raising a latissimus dorsi myoadipose flap from the same incision used for axillary clearance, offers excellent cosmetic and oncologic results [20].

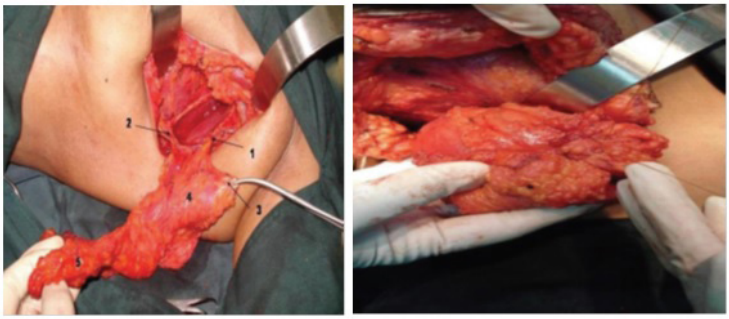

Figure 26: (a) Myoadipose flap with details. (b) Flap rolled with loose sutures to provide bulk.
1. Thoracodorsal pedicle. 2. Communicating branch to the lateral thoracic vessel. 3. Tendon severed from humerus to increase mobility to the flap. 4. Proximal part of muscle tissue devoid of fat.5. Dissection of axillary fat overlying the flap.

In breast-conservative therapy (BCT), it is difficult to repair defects in the inferior portion of the breast. To address this problem; Tomoko Ogawa et al (2007) performed an immediate reconstruction using an inframammary adipofascial flap after breast conservation in 4 patients with breast cancer in the inferior portion of their breasts and evaluated the usefulness of the procedure. A skin incision was made at the inframammary line. Immediately following BCT, a tongue-shaped flap of the fat and the anterior sheath of the rectus abdominis muscle were pulled up and inserted to reconstruct the breast mound. The cosmetic outcomes of all patients were good, and this surgical pro-

cedure can be easily performed by general surgeons without the need of assistance by plastic surgeons. The authors believe this to be a useful surgical modality for the reconstruction of BCT in the inferior portion breast cancer [21].

Corrective surgery after breast-conserving surgery is usually challenging due to severe fibrosis induced by postoperative radiotherapy. The latissimus dorsi myocutaneous (LDM) flap has high vascularity and is associated with fewer risk factors, and therefore, it will likely afford improved aesthetic outcomes [22]. Although use of the LDM flap is a safe and reliable option, exposure of the skin paddle to radiotherapy is often inevitable, leaving conspicuous, patchwork-like scars on the breast. Therefore, achieving correction of any nipple-areola complex malposition often becomes very difficult. To address this concern, Tomita et al (2014), described a 2-stage procedure using a subcutaneous tissue expander (first) and then the latissimus dorsi myocutaneous flap for the correction of both nipple-areola complex malposition and breast volume, without skin paddle exposure. However, a careful observation is important during skin expansion. The authors are off the view that this technique could offer an alternative option for patients undergoing corrective surgery following breast-conserving surgery [23].

Cavity Shaving

Routine cavity shaving (excision of all margins around the cavity left by partial mastectomy) may reduce

the rates of positive resection margins (margins positive for tumor) and re-excision rates among patients undergoing partial mastectomy for breast cancer. However, it is still debated that whether it should be performed routinely or selectively.

Figure 27: Marking of skin for re excision.

Figure 28: Appearance after closure of 2nd surgery.

Figure 29: The final appearance.

In a recent prospective randomized control trial, Chagpar et al randomized 235 patients with stage 0 to III breast cancers who were undergoing breast conserving surgery, into routine shave group and no shave group. After randomization it was noted that the routine shave group had a significantly lower level of positive margins (19% vs. 34%, P=0.01) and second surgery for margin clearance (10% vs. 21%, P=0.02) in the routine shave group compared to the no-shave group. The author thus concluded that routine cavity shaving should be considered in all patients undergoing breast conserving surgery [24].

Opposite Breast (OB) Surgery

Another important issue is related to OB surgery. Munhoz et al, in their series, have found that all patients who underwent reduction mammoplasty reconstruction had bilateral procedures [25-29] and almost 40% of patients who had volume replacement underwent a contralateral breast surgery, in order to achieve a satisfactory cosmetic outcome.

In fact, Kronowitz et al (2007), observed a significant relationship existing between the re-constructive technique and the need for an OB reduction [30]. This aspect can be viewed as a negative point, however it also has the advantages of allowing for sampling of glandular tissue [19,25-27].

In a recent study, Munhoz et al. documented their experience with surgical management and outcome in

BCS reconstruction with bilateral mammoplasty (BM) techniques, with regard to whether immediate or delayed reconstruction is better in terms of complication rates. In this series, in three patients (2.8 per cent) an unexpected cancer in the opposite breast was observed with immediate reconstruction. Although the diagnosis of occult cancer is not a reason to perform an OB reduction, this procedure can be advantageous for high-risk patients and especially for patients with previous breast cancer [19].

Advantages of Reduction mammoplasty
• It decreased the size of the opposite breast > improve balance of the two breasts and the entire body. • It also decreased back pain and shoulder pain. • It allows detection of occult breast lesions • Improves safety of the resection margin after partial mastectomy • Easier to use postoperative radiation>> radiotherapy complications can be decreased.

Timing of Reconstruction

This can be immediate, delayed-immediate or delayed. Currently, there is no consensus concerning the best approach. The criteria are determined by the surgeon's experience and the size of the defect, in relation to the size of the remaining breast [31].

With an immediate oncoplastic approach, the surgical process is smooth, since oncological and reconstructive surgery can be performed in one operative setting. Ad-

ditionally, because there is no scar or fibrotic tissue, breast reshaping is easier, and the aesthetic outcome is improved [15,16,32-34]. In fact, Papp et al, 1998 [34] and Rainsbur et al, 2012 [9] observed that the aesthetic results showed a higher success rate in the immediate group when compared with delayed reconstruction patients. Similarly, Kronowitz et al, 2006, observed that immediate repair is preferable to delayed, because of a decreased incidence of complications [15]. The author noticed that when utilizing reduction-mammoplasty techniques for BCS reconstruction, the post-radiation complication rate (delayed BCS reconstruction) was higher than that expected for mammoplasty without radiotherapy [36]. After adjusting for other risk factors, the probability of complications tends to be higher in the delayed reconstruction group. This finding is similar to published reports that suggest that delayed BCS reconstruction has a significantly higher complication rate compared with immediate procedures [15,16].

Immediate oncoplastic reconstruction can be advantageous for both oncological resection and adjuvant treatment. Some clinical series have observed that patients with large volume breasts present more radiation-related complications than patients with normal volume breasts [37-39]. Additionally, some authors have suggested that there is an increased fat content in large breasts and the fatty tissue results in more fibrosis after radiotherapy than

glandular tissue. Gray et al, 1991, in a clinical series, observed that there was more retraction and asymmetry in the large-breasted versus the small breasted group. Therefore, breast reduction can increase the eligibility of large-breasted patients for BCS since it can reduce the difficulty of providing radiotherapy [25-29,37,40].

Another aspect of timing of reconstruction is the possibility of accomplishing negative resection margins. In fact, immediate reconstruction allows a wider margin of tumour resection, and thereby potentially reducing the incidence of margin involvement [25-29,40,41].

Figure 30: Relatively Larger Resected specimen by oncoplastic surgery.

The oncoplastic approach also permits larger resections, with a superior mean volume of the specimen and negative margins as clearly shown in our patients. In spite of the benefits, the immediate reconstruction presents limitations. The surgical time can be lengthened, and it requires specialist training to learn and properly apply these procedures [25-29,42]. Thus, delayed reconstruction

can be advantageous in some specific groups of patients. In fact, in some cases the final contour of the breast cannot be predicted at the time of the BCS [40]. In addition, it is well accepted that radiation usually involves some degree of fibrosis and shrinkage. Some authors observed that although the aesthetic outcome can be satisfactory, the appearance of the radiated breast is occasionally less pleasing than the non-radiated one [40,43-45]. Thus, in delayed reconstruction, the plastic surgeon waits until the postoperative changes in the deformed breast stabilize.

Another important point is related to the postoperative recovery. In theory, some complications of immediate reconstruction can unfavourably defer adjuvant therapy. With delayed oncoplastic reconstruction, operative time is shortened and the surgical process is less extensive than in an immediate reconstruction. However, findings from Munhoz et al [25-29,33] and others [16,18,40] have shown that immediate reconstruction does not compromise the start of radio- and chemotherapy in the overall treatment of breast cancer.

Techniques of Breast Reconstruction

The ideal breast reconstruction is a soft natural feeling breast which maintains its characteristics over time, has a natural fluidity and a permanent and natural inframammary fold.

Implant Based Techniques

Require limited surgery initially but has certain limitations and is not always quick and trouble-free. These procedures allow patients some control over breast size, but the quality of the long-term result is directly related to their tolerance of breast implants. Further procedures may be required for complications and maintenance.

Autologous Techniques

The autologous latissimus dorsi flap is highly versatile and has acceptable donor site morbidity. The aesthetic results from autologous reconstruction are superior to those of implant based reconstruction due to their versatility, their more natural appearance, consistency and durability. Autologous tissue can better withstand radiotherapy [45].

Types of Autologous Flaps

(1) Latissimus dorsi flaps

- Muscle only flap, without a skin island
- Myocutaneous flap with or without a breast implant or tissue expander
- Extended LD flap reconstructing the whole breast with autologous tissues only, avoiding the use of implants or tissue expanders
- Muscle sparing or perforator based techniques

(2) Transverse rectus abdominis myocutaneous flaps

- Free transverse rectus abdominis myocutaneous flap (TRAM)
- Pedicled transverse rectus abdominis myocutaneous flap (TRAM)

(3) Free deep inferior epigastric perforator flap (DIEP)

(4) Free superficial inferior epigastric artery flap (SIEA)

The muscle sparing techniques preserve the abdominal wall function at a cost of a more complex procedure. The choice of technique depends on:

- Breast size
- Laxity and thickness of remaining breast skin
- Stage of disease
- Body habitus
- Patient fitness for surgery
- Availability of donor flap sites
- Condition of the underlying muscles
- The need for adjuvant radiotherapy
- Patient choice if more than one reconstructive option is feasible [46-48].

Tissue Expansion and Implant Reconstruction

Replacement of the breast volume with a tissue expander or an implant is the simplest method of breast reconstruction [49]. However, patient and implant selection are off paramount importance. The available techniques are as follows:

- Variable volume expander-implant (single stage)
- Fixed volume implant (single stage)
- Tissue expansion followed by permanent implant (two stage)

Advantages of Tissue Expansion

- Simple and flexible technique
- Shorter procedure
- Shorter convalescence and rehabilitation
- Avoids donor site morbidity
- Allows insertion of larger implants
- May not involve additional scarring
- Breast is reconstructed with local skin
- Does not preclude further reconstruction options

Disadvantages of Tissue Expansion

- Need for revision surgery
- Lack of projection
- Limited ptosis
- Less likely to achieve symmetry
- Less satisfactory long-term cosmetic outcome
- Required multiple staged procedures
- Multiple hospital visits for expansion
- Added complications of implants
- Capsular contracture particularly after adjuvant radiotherapy [50-52].

Indications for Tissue Expansion [47]

- Small to moderate non-ptotic breasts
- Good soft tissue cover, intact pectoralis major muscle
- Bilateral reconstruction
- Patient of normal body mass index (BMI)
- Patients who are unwilling or unfit to undergo autologous tissue reconstruction

Contraindications for Tissue Expansion [47]

- Mastectomy skin deficit >8 cm
- Radical mastectomy defect
- Chest wall tissues are thin, damaged, inelastic or irradiated
- Extensive infra-clavicular tissue deformity or a vertical mastectomy scar
- Patients who have unresolved concerns about the use of implants
- The complications of implant

Nipple Areola Reconstruction

The final part of the breast reconstruction is the reconstruction of the nipple areola complex. Some patients are happy with a prosthetic nipple but patients should be offered the opportunity to proceed to nipple reconstruction.

The techniques for nipple reconstruction are prosthetic nipple, local flap reconstruction and composite grafts. Similarly the techniques for areola reconstruction are tattooing and full thickness skin grafts. However, the use of skin grafts has largely been abandoned in favour of a relatively simple technique of tattooing with few complications.

Clinical Results of Oncoplastic Breast Surgery

The clinical results of oncoplastic breast surgery largely depend on performing optimal surgery. However, it is challenging for oncological and plastic surgeons to choose an optimal surgery for these patients, because of constraints of our healthcare systems, as well as different social & cultural backgrounds of these patients. At the present time, optimal treatment should be correct, adequate and preventative, by performing immediate reconstruction before radiotherapy [15,19,53]. However, until recently there was limited evidence in the plastic and breast surgery literature on the safety and aesthetic clinical results of the oncoplastic techniques. In fact, the greater part of these clinical series are retrospective studies, generally based on a limited number of patients and sometimes only a single surgeon's experience. In addition, there is little data on its impact on local recurrences, distant metastasis and overall survival. Kronowitz et al, in 2006, in a review of 69 patients observed local recurrence in 2% of immediate oncoplastic reconstructions and in 16% of delayed (P=0.06). The difference observed between the two groups can be explained by the advanced tumour stage for the patients who had a delayed reconstruction. Similarly, Clough et al, with a median follow-up of 46 months, reported 101 patients who were underwent BCS and oncoplastic reconstruction. Local recurrence developed in 11 cases (5-year

local recurrence rate was 9.4%). Thirteen patients developed metastases and eight died of their disease (5-year metastasis-free survival of 82.8% and an overall survival rate of 95.7%). Rietgens et al. (2007) reported the long-term oncological results of the oncoplastic reconstruction in a series of 148 patients. With a median follow-up of 74 months, 3% developed an ipsilateral breast cancer recurrence and 13% developed distant metastasis [36]. According to the authors, the rate of local recurrence after 5 years was low in their series when compared with the 14.3% of cumulative incidence in the NSABP trial, the 9.4% after 5 years in the Institute Curie study and the 0.5% after 5 years in the Milan I trial. Consequently, the oncoplastic approach associated with BCS can be considered as safe as mastectomy in tumours less than 2 cm. Recognizing that there is a small risk for local recurrence, and based on clinical series previously published, we believe that immediate application of oncoplastic procedures could be a reasonable and safe option for early-breast-cancer patients who desire BCS.

The long term oncological outcome of oncoplastic breast surgery was not known before. Most of the studies are either small case series or with short term follow up. Recently La Cassi et al, in a comparative of 211 breast cancer patient noted a minimal difference in local recurrence and number of distal metastasis with no difference in long term survival [54].

Similarly, the long term safety of the oncoplastic surgery was assessed by De Lorenzi et al in their recent study. They compared 454 consecutive breast cancer patients (study group) who underwent an oncoplastic breast surgery with twice the number of breast cancer patients (908) who received standard breast conservation(control group) during the same period of time . The median follow-up time was 7.2 years. There was no statistically significant difference between the groups with respect to overall survival (91.4% vs 91.3%) at 10-yrs follow up. Although, in the oncoplastic group (69 vs.73.1% at 10-yr) the disease free survival was slightly lower however the noted difference was not statistically significant [55].

Limitations of Oncoplastic Breast Surgery

One of the limitations of the breast reconstruction at the time of oncoplastic surgery is that the additional procedure would result in complications and delay adjuvant therapy. In a recently published meta-analysis, the average complication rate in the oncoplastic reduction mammoplasty group was 16%, and in the oncoplastic flap reconstruction group was 14% [56]. However, there was no delay in the initiation of adjuvant therapy.

According to the authors, it does not seem that complications in the oncoplastic groups, although potentially higher, have any negative impact on patient care from an oncologic point of view. In fact, adequate technique and

patient selection is crucial in order to minimize morbidity when these oncoplastic techniques are selected [56,57].

However, recent evidence suggests that this is not quite true. The American College of Surgeons

NSQIP (National Surgical Quality Improvement Program) database confirms that the use of oncoplastic breast surgery does not increase the risk of surgical complications, despite the longer operative time [58].

Concerning late complications, the most common event is related to fat necrosis. Glandular necrosis is a pertinent issue affecting volume displacement techniques and is more likely to occur with type I procedures than with excision alone, due to the greater glandular mobilisation. This is a particular problem when the breast is predominantly made up of fatty rather than glandular tissue, and there is extensive mobilisation of the tissue with wide areas of skin undermining and dissection of the gland from pectoralis major [10]. Areas of fat necrosis may ultimately become infected, leading to post-operative healing problems and potential delays in adjuvant therapies. In order to reduce the risk of glandular necrosis, as mentioned previously, an assessment of glandular density as part of the pre-operative surgical planning is particularly important. Patients can then be offered appropriate procedures on an individual basis. Munhoz et al, in their series compared immediate and delayed BCS reconstruction with reduction mammoplasty techniques and found that fat necrosis was significantly higher in the delayed group [19]. The au-

thor concluded that radiation therapy played a significant role and contributed to the development of fat necrosis. In delayed reconstructions, a slower re-establishment of a local blood supply to rearranged breast tissues from the underlying irradiated chest wall is usually observed. In addition, the local effects of radiotherapy and previous breast tissue scarring can also disrupt the local blood supply and the ability to create a safe parenchymal pedicle [15,19]. Thus, in these patients, careful surveillance is prudent since the risk of local recurrence is always possible. According to Losken et al. postoperative surveillance is not impaired by simultaneous BM. In some cases, calcifications and fat necrosis can simulate tumour recurrence; however, these aspects can be distinguished on mammogram or needle-core biopsy [25-29].

Postoperative Radiation and Boost Therapy Planning: Oncoplastic Safety

It remains a standard of care to use adjuvant radiotherapy in all patients undergoing breast conserving surgery, regardless of technique. There is an established body of evidence within the literature from randomised controlled trials that reports significantly lower rates of local recurrence and better oncological outcomes if BCS is used in combination with adjuvant radiotherapy compared to surgery alone [59].

Current literature supports the use of oncoplastic breast surgery, in comparison to historical standard tech-

niques. Clough et al., have reported a prospective analysis of a 100-patient series undergoing the more complex type of oncoplastic breast surgery, with 5-year overall and disease-free survival rates of 95.7% and 82.8% respectively [60]. Rietjens et al., have reported an overall local recurrence rate of 3% in their series involving similar surgical techniques [36]. Although, recent systematic review of the oncoplastic breast conserving surgery demonstrated higher rates of complications, but these did not impact on delays in adjuvant therapies or oncological outcomes [61].

In fact, there are now increasing evidence that reduction mammoplasty techniques, can result in excision of the tumour with wider surgical margins and more effective radiotherapy planning [18,60,61]. Clarke et al, 2005, reported that patients with large, pendulous breasts receive a much higher dose of radiation with the standard breast conserving surgery, and hence demonstrates the advantage of a reduction in breast size achieved with mammoplasty techniques [3].

Comparative Study on Local Recurrence and BCT with Oncoplastic Techniques

Chakravorty et al, 2012, in a prospective study, compared re-excision and LR rates with 28 month median follow up-440 sBCS and 150 oBCS (in 146 women). The median size of the tumour was 21 mm vs.18mm and the median specimen weight was 67g vs. 40 g ($p < 0.001$). The

re-excision rate was 2.7% (4/150) for oBCS and 13.4% (59/440) for sBCS ($p < 0.001$). The local relapse rate was 2.7% (4) for oBCS vs 2.2% (10) for sBCS, and the distant relapse rate was 1.3% for oBCS versus 7.5% for sBCS [63].

A recent meta-analysis by Losken et al, 2013, compared BCT with oncoplastic reduction techniques and BCT with oncoplastic flap techniques with BCT alone technique. A total of 61 papers were reviewed. Comparisons were made on 5494 patients in the BCT alone group (20 papers) and 3165 patients in the BCT with oncoplastic group (41 papers). Demographics were similar, and tumour size was larger in the oncoplastic group (2.7 vs. 1.2 cm). The weight of the lumpectomy specimen was 4 times larger in the oncoplastic group. The positive margin rate was significantly lower in the oncoplastic group (12% vs. 21%, $P < 0.0001$). Re-excision was more common in the BCT alone group (14.6% vs. 4%, $P < 0.0001$), however completion mastectomy was more common in the oncoplastic group (6.5% vs. 3.79%, $P < 0.0001$). Local recurrence was 4% in the oncoplastic group and 7% in the BCT alone group. However, the cosmetic satisfaction was significantly higher in the oncoplastic group (89.5% vs. 82.9%, $P < 0.001$). The author concluded that a generous resection can be done with the oncoplastic approach with subsequent reduction in positive margins [56].

Halou et al, 2013 in a systematic review of 2090 abstracts on the topic of oncoplastic breast surgery(OPBS); between 2000 and 2011 has identified a total of 88 articles

- no RCTs were identified, 11 prospective observational or comparative studies fulfilled inclusion criteria. 80% to 93% of the tumours were invasive with tumour-free resection margins of 78% to 93% and mastectomy rate of 3% to 16%. Local recurrence rate was 0% to7% with a good cosmetic outcome in 84% to 89% of the cases [64].

Comparative Study on Cosmetic Outcomes and BCT with Oncoplastic Techniques

The methods of aesthetic evaluation vary significantly [15]. Some authors reported that the amount of glandular and skin tissue resection is directly associated to the aesthetic outcome. Olivotto et al. and Mills et al, (1989) have

documented that excision of a volume greater than 70 cm3 in medium-size breasts often leads to unsatisfactory aesthetic results [65]. Gendy et al. retrospectively compared the aesthetic outcomes of 106 patients. Although the panel scored the cosmetic outcome quite high, the cosmetic failure rate was 18% on breast retraction assessments. The authors demonstrated an advantage for the BCS reconstruction with regard to the incidence of complications (8% versus 14%), additional surgery (12% versus 79%) and restricted activities (54% versus 73%) [66]. Clough et al, in a panel of three, assessed cosmetic results at 2 and 5 years. At 2 years, 88%, and at 5 years, 82% of patients had a fair to excellent outcome. A significantly worse aesthetic outcome was observed in patients that received preoperative radiotherapy compared to the patients who received radiotherapy post-operatively (poor outcome 42.9 vs. 12.7%, $P<0.02$) [16].

Recent meta-analysis by Losken et al, 2013 has clearly documented the aesthetic superiority of oncoplastic surgery over standard BCS (89.5% vs. 82.9%, $P < 0.001$) [56]. Similar findings were also reported by another recent systematic review by of 2090 abstracts on the topic of oncoplastic breast surgery (OPBS) by Haloua et al, 2013, and it was found that good cosmetic results are achieved in 84% to 89% of the patients undergoing oncoplastic breast surgery [64] .

In a response to a letter to the editor Carmichael et al, 2017, commented that it is possible to obtain both oncologic and aesthetic benefits in a vast majority of these patients with adequate training, proper planning, and utilizing unique surgical techniques [5].

Comparative Study on Quality of Life and BCT with Oncoplastic Techniques

The debate of whether oncoplastic surgery has improved the quality of life and self esteem among breast cancer patients is ongoing. However, a recent prospective study provides sufficient evidence to claim its superiority over standard BCS. Veiga et al, 2010, in a prospective trial compared the quality of life and self-esteem between 45 patients who had BCS with reconstruction and 42 patients who had BCS without reconstruction, and followed up at 6 & 12 months. Both groups were matched for age, body mass index, and demographic and oncologic aspects. At 12 months, the author found that the scores were significantly higher in breast reconstruction group and they had significantly better health status than the control group, with regard to physical functioning, health perception & vitality, social functioning & role, emotional and mental health and self-esteem. Hence, the author concluded that oncoplastic surgery had a positive impact on quality of life and self-esteem of patients undergoing breast-conserving treatment [67].

Conclusion

Oncoplastic breast conservation surgery is a significant advancement in the surgical management of breast cancer. It facilitates the removal of large volumes of breast tissue with significantly improved cosmetic outcomes and patient satisfaction, whilst maintaining good oncological principles, potentially reducing re-excision and mastectomy rates and assisting in adjuvant radiotherapy planning.

Despite the popularity of BCS, discussions regarding cosmetic results after BCS are not specifically conducted. The simple conservation of breast tissue is no longer adequate to qualify for BCS completion. More research should be actively pursued to achieve symmetry with the contralateral breast after BCS and radiotherapy, as well as patient satisfaction with breast cosmetics. The volume displacement technique using oncoplastic principles allows the use of remaining breast tissue after BCS by glandular reshaping or reduction techniques for better cosmetic results. Thorough understanding of these procedures and careful consideration of the patient's breast size, tumour location, excised volume, and volume of the remaining breast tissue during the surgery in choosing appropriate patients and surgical techniques, will result in good cosmetic results. However one should not compromise oncological safety at the expense of attainment of aesthetic excellence. The importance of adequate training cannot be overemphasized. Immediate reconstruction is not always necessary when using oncoplastic procedures. Patients'

high risk for positive margins, delaying the procedure for a few weeks or after radiotherapy remains as a viable option. However, in few cases collaboration between the breast surgeons and the plastic surgeons can limit the adverse aesthetic sequelae.

References

1. Fisher B, Anderson S, Bryant J, Margolese RG, Deutsch M, et al. Twenty-year follow-up of a randomized trial comparing total mastectomy, lumpectomy, and lumpectomy plus irradiation for the treatment of invasive breast cancer. N Eng. J Med. 2002; 347: 1233-1241.
2. Veronesi U, Cascinelli N, Mariani L, Greco M, Saccozzi R, et al. Twenty-year follow-up of a randomized study comparing breast-conserving surgery with radical mastectomy for early breast cancer. N Eng. J Med. 2002; 347: 1227-1232
3. Clarke M, Collins R, Darby S, Davies C, Elphinstone P, et al. Effects of radiotherapy and of differences in the extent of surgery for early breast cancer on local recurrence and 15-year survival: an overview of the randomised trials. Lancet. 2005; 366: 2087-2106.
4. Berrino P, Campora E, Santi P. Post-quadrantectomy breast deformities: classification and techniques of surgical correction. Plast Reconstruct Surg 1987; 79: 567-572.

5. Carmichael AR and Mokbel K. Response to Letter: Evolving Trends in Breast Surgery: Oncoplastic to Onco-Aesthetic Surgery. Arch Plast Surg. 2017; 44: 86.

6. Gabka CJ, Maiwald G, Baumeister RG .Expanding the indications spectrum for breast saving therapy of breast carcinoma by oncoplastic operations. Langenbecks Arch Chir Suppl Kongressbd. 1997; 114: 1224-1227.

7. Audretsch WP. Reconstruction of the partial mastectomy defect: classification and method. Surgery of the breast: principles and art. Philadelphia: Lippincott Raven. 1998.

8. Werner P Audretsch, Mahdi Rezai, Christos Kolotas, Nikolaos Zamboglou, Thomas Schnabel, et al .Tumor-specific immediate reconstruction in breast cancer patients .Persp Plast Surg. 1998; 11: 71-100.

9. Rainsbury D, Willett A. Oncoplastic breast reconstruction: guidelines for best practice. UK: ABS & BAPRAS. 2012. http://www.associationofbreastsurgery.org.uk/media /23851/final_oncoplastic_guidelines_for_use.pdf

10. Clough KB, Kaufman GJ, Nos C, Buccimazza I, Sarfati IM, et al. Improving breast cancer surgery: a classification and quadrant per quadrant atlas for oncoplastic surgery. Ann Surg Oncol. 2010; 17: 1375-1391.

11. Bulstrode NW, Shrotria S. Prediction of cosmetic outcome following conservative breast surgery using breast volume measurements. Breast. 2001; 10: 124-126.

12. Clough KB, Soussaline M, Campana F, Salmon RJ. Mammoplasty combined with irradiation: conservative treatment of breast cancer localized in the lower quadrant. Ann Chir Plast Esthet. 1990; 35: 117-122.

13. Association of Breast Surgery at BASO, Association of Breast Surgery at BAPCRAS, Training Interface Group in Breast Surgery, et al. Oncoplastic breast surgery-a guide to good practice; Eur J Surg Oncol. 2007; 33: S1-23.

14. da CostaVieiraa RA, Angotti Carraraa GF, Netoc CS, Morinic MA, Brentanid MM, et al. The role of oncoplastic breast conserving treatment for locally advanced breast tumors; A matching case-control study. Annals of Medicine and Surgery. 2016; 10: 61-68.

15. Kronowitz SJ, Feledy JA, Hunt KK, Kuerer HM, Youssef A, et al. Determining the optimal approach to breast reconstruction after partial mastectomy. Plast Reconstruct Surg. 2006; 117: 1-11.

16. Clough KB, Thomas SS, Fitoussi AD, Couturaud B, Reyal F, et al. Reconstruction after conservative treatment for breast cancer: cosmetic sequelae

classification revisited .Plast Reconstr Surg. 2004; 114: 1743-1753.

17. Munhoz AM, Montag E, Fels KW, Arruda EG, Sturtz GP, et al. Outcome analysis of breast-conservation surgery and immediate latissimus dorsi flap reconstruction in patients with T1 to T2 breast cancer. Plast Reconstr Surg. 2005; 116: 741-752.

18. Spear SL, Pelletiere CV, Wolfe AJ, Tsangaris TN, Pennanen MF. Experience with reduction mammoplasty combined with breast conservation therapy in the treatment of breast cancer. Plast Reconstruct Surg. 2003; 111: 1102-1109.

19. Munhoz AM, Aldrighi CM, Montag E, Arruda E, Brasil JA, et al. Outcome analysis of immediate and delayed conservative breast surgery reconstruction with mastopexy and reduction mammaplasty techniques. Ann Plast Surg. 2011; 67: 220-225.

20. Naraynsingh V, Seetharaman Hariharan, Dilip Dan. Immediate breast reconstruction following segmentectomy using a latissimus dorsi 'myoadipose' flap through a single axillary incision: a case series. Cases Journal. 2009; 2: 8116.

21. Tomoko Ogawa, Noriko Hanamura, Masako Yamashita, Yuki Ri, Naohisa Kuriyama, et al. Usefulness of breast-volume replacement using an

inframammary adipofascial flap after breast-conservation therapy. The American Journal of Surgery. 2007; 193: 514–518.

22. Koichi Tomita, Kenji Yano, Akimitsu Nishibayashi, Megumi Fukai, Miwako Miyasaka, et al. The role of latissimus dorsi myocutaneous flaps in secondary breast reconstruction after breast-conserving surgery. Eplasty. 2013; 13: 28.
23. Koichi Tomita, Kenji Yano, Yuta Sugio, Takayoshi Ishihara, Akimitsu Nishibayashi, et al. Breast Reconstruction following Breast-conserving Surgery with a Subcutaneous Tissue Expander and Latissimus Dorsi Flap; Plastic and Reconstructive Surgery - Global Open. 2014; e231.
24. Chagpar AB, Killelea B, Tsangaris TN, Horowitz NR. A Randomized, Controlled Trial of Cavity Shave Margins in Breast Cancer, New England Journal of Medicine. 2015; 373.
25. Munhoz AM, Montag E, Arruda EG, Aldrighi C, Gemperli R, et al. Critical analysis of reduction mammaplasty techniques in combination with conservative breast surgery for early breast cancer treatment. Plast Reconstr Surg. 2006; 117: 1091-1103.
26. Munhoz AM, Montag E, Arruda EG, et al. The role of the lateral thoracodorsal fascio-cutaneous flap in immediate conservative breast surgery

reconstruction; Plast Reconstr Surg 2006; 117: 1699-710

27. Munhoz AM, Montag E, Arruda EG, Aldrighi C, Gemperli R, et al. Superior-medial dermoglandular pedicle reduction mammaplasty for immediate conservative breast surgery reconstruction. Ann Plast Surg. 2006; 57: 502-508.
28. Munhoz AM, Aldrighi CM, Ferreira MC. Paradigms in oncoplastic breast surgery: a careful assessment of the oncological need and aesthetic objective. Breast J. 2007; 13: 326-327.
29. Munhoz AM, Montag E, Arruda E, Aldrighi C, Filassi JR, et al. Reliability of inferior dermoglandular pedicle reduction mammaplasty in reconstruction of partial mastectomy defects: surgical planning and outcome. Breast. 2007; 16: 577-589.
30. Kronowitz SJ, Hunt KK, Kuerer HM, Strom EA, Buchholz TA, et al. Practical guidelines for repair of partial mastectomy defects using the breast reduction technique in patients undergoing breast conservation therapy. Plast Reconstr Surg. 2007; 120: 1755–1768.
31. Asgeirsson KS, Rasheed T, McCulley SJ, Macmillan RD. Oncological and cosmetic outcomes of oncoplastic breast conserving surgery. Eur J Surg Oncol. 2005; 31: 817-823.

32. Slavin SA, Halperin T. Reconstruction of the breast conservation deformity. Semin Plast Surg. 2004; 18: 89-96.

33. Munhoz AM, Montag E, Arruda E, Pellarin L, Filassi JR, et al. Assessment of immediate conservative breast surgery reconstruction: a classification system of defects revisited and an algorithm for selecting the appropriate technique. Plast Reconstr Surg. 2008; 121: 716-727.

34. Papp C, Wechselberger G, Schoeller T. Autologous breast reconstruction after breast-conserving cancer surgery. Plast Reconstr Surg. 1998; 102: 1932-1936.

35. Rainsbury D, Willett A. Oncoplastic breast reconstruction: guidelines for best practice. London: Association of Breast Surgery. 2012.

36. Rietjens M, Urban CA, Rey PC, Mazzarol G, Maisonneuve P, et al. Long-term oncological results of breast conservative treatment with oncoplastic surgery. Breast. 2007; 16: 387-395.

37. Chang E, Johnson N, Webber B, Booth J, Rahhal D, et al. Bilateral reduction mammoplasty in combination with lumpectomy for treatment of breast cancer in patients. Am J Surg. 2004; 187: 647-650; discussion 650-651.

38. Brierley JD, Paterson IC, Lallemand RC, Rostom AY. The influence of breast size on late radiation

reaction following excision and radiotherapy for early breast cancer. Clin Oncol (R Coll Radiol). 1991; 3: 6-9.

39. Gray JR, McCormick B, Cox L, Yahalom J. Primary breast irradiation in large-breasted or heavy women: analysis of cosmetic outcome. Int J Radiat Oncol Biol Phys. 1991; 21: 347-354.
40. Losken A, Elwood ET, Styblo TM, Bostwick J 3rd. The role of reduction mammaplasty in reconstructing partial mastectomy defects. Plast Reconstr Surg. 2002; 109: 968-975.
41. Kaur N, Petit JY, Rietjens M, Maffini F, Luini A, et al. Comparative study of surgical margins in oncoplastic surgery and quadrantectomy in breast cancer. Ann Surg Oncol. 2005; 12: 539-545.
42. Hamdi M, Wolfli J, Van Landuyt K. Partial mastectomy reconstruction. Clin Plast Surg. 2007; 34: 51-62.
43. Huemer GM, Schrenk P, Moser F, Wagner E, Wayand W. Oncoplastic techniques allow breast-conserving treatment in centrally located breast cancers. Plast Reconstruct Surg. 2007; 120: 390-398.
44. Clough KB, Kroll SS, Audretsch W. An approach to the repair of partial mastectomy defects. Plast Reconstr Surg. 1999; 104: 409-420.

45. Eberlein TJ, Crespo LD, Smith BL, Hergueter CA, Douville L, et al. Prospective evaluation of immediate reconstruction after mastectomy. Ann Surg. 1993; 218: 29–36.

46. Handel N, Silverstein MJ, Waisman E, Waisman JR. Reasons why mastectomy patients do not have breast reconstruction. Plast Reconstr Surg. 1990; 86: 1118–1122.

47. Bostwick III J. Plastic and reconstructive breast surgery. St. Louis, Missouri: Quality Medical Publishing. 1990.

48. Tzafetta K, Ahmed O, Bahia H, Jerwood D, Ramakrishnan V. Evaluation of the factors related to postmastectomy breast reconstruction. Plast Reconstr Surg. 2001; 107: 1694–701.

49. Radovan C. Breast reconstruction after mastectomy using the temporary expander; Plastic Reconstr Surg. 1982; 69: 195–208.

50. Woods JE, Mangan MA. Breast reconstruction with tissue expanders: obtaining an optimal result. Ann Plast Surg. 1982; 69: 195–208.

51. Gabriel SE, Woods JE, O'Fallon WM, Beard CM, Kurland LT, et al. Complications leading to surgery after breast implantation; N Engl J Med. 1997; 336: 677–682.

52. Clough KB, O'Donoghue JM, Fitoussi AD, Vlastos G, Falcou M-C. Prospective evaluation of late cosmetic results following breast reconstruction: II. TRAM flap reconstruction. Plast Reconstr Surg. 2001; 107: 1710–1716.

53. Losken A, Styblo TM, Carlson GW, Jones GE, Amerson BJ. Management algorithm and outcome evaluation of partial mastectomy defects using reduction or mastopexy techniques. Ann Plast Surg. 2007; 59: 235-242.

54. La Cassi C, Vanni G, Petrella G, Orsaria P, Pistolese C, et al. Comparative study of oncoplastic versus non-oncoplastic BCS in a group of 211 breast cancer patients. European Review for Medical and Pharmacological Sciences. 2016; 20: 2950-2954.

55. De Lorenzi F, Hubner G, Rotmensz N, Bagnardi V, Loschi P, et al. Oncological results of oncoplastic breast-conserving surgery: Long term follow-up of a large series at a single institution: A matched-cohort analysis. Eur J Surg Oncol. 2016; 42: 71-77.

56. Losken A, Dugal CS, Styblo TM, Carlson GW. A meta-analysis comparing breast conservation therapy alone to the oncoplastic technique. Ann Plast Surg. 2014; 72: 145-149.

57. Fitoussi AD, Berry MG, Famà F, Falcou MC, Curnier A, et al. Oncoplastic breast surgery for

cancer: analysis of 540 consecutive cases. Plast Reconstr Surg. 2010; 125: 454-462.

58. Cil TD, Cordeiro E. Complications of oncoplastic breast surgery involving soft tissue transfer versus breast-conserving surgery: an analysis of the NSQIP database. Ann Surg Oncol. 2016; 23: 3266–3271.

59. Vinh-Hung V, Verschraegen C. Breast-conserving surgery with or without radiotherapy: pooled-analysis for risks of ipsilateral breast tumor recurrence and mortality. J Natl Cancer Inst. 2004; 96: 115-121.

60. Clough KB, Lewis JS, Couturaud B, Fitoussi A, Nos C, et al. Oncoplastic techniques allow extensive resections for breast-conserving therapy of breast carcinomas. Ann Surg. 2003; 237: 26-34.

61. McIntosh J, O'Donoghue JM .Therapeutic mammoplasty a systematic review of the evidence. Eur J Surg Oncol. 2012; 38: 196-202.

62. Veronesi U, Marubini E, Mariani L, Galimberti V, Luini A, et al. Radiotherapy after breast-conserving surgery in small breast carcinoma: long-term results of a randomized trial. Ann Oncol. 2001; 12: 997-1003.

63. Chakravorty A, Shrestha AK, Sanmugalingam N, Rapisarda F, Roche N, et al. How safe is onco-

plastic breast conservation? Comparative analysis with standard breast conserving surgery. Eur J Surg Oncol. 2012; 38: 395-398.

64. Haloua MH, Krekel NM, Winters HA, Rietveld DH, Meijer S, et al. A systematic review of oncoplastic breast-conserving surgery: current weaknesses and future prospects. Ann Surg. 2013; 257: 609-620

65. Olivotto IA, Rose MA, Osteen RT, Love S, Cady B, et al. Late cosmetic outcome after conservative surgery and radiotherapy: analysis of causes of cosmetic failure. Int J Radiat Oncol Biol Phys. 1989; 17: 747-753.

66. Gendy RK, Able JA, Rainsbury RM. Impact of skin-sparing mastectomy with immediate reconstruction and breastsparing reconstruction with miniflaps on the outcomes of oncoplastic breast surgery. Br J Surg. 2003; 90: 433-439.

67. Veiga DF, Veiga-Filho J, Ribeiro LM, Archangelo I Jr, Balbino PF, et al. Quality-of-life and self-esteem outcomes after oncoplastic breast-conserving surgery. Plast Reconstr Surg. 2010; 125: 811-817.