

See discussions, stats, and author profiles for this publication at: <https://www.researchgate.net/publication/301324845>

# Paraclavicular approach to thoracic decompression with axillary to internal jugular vein bypass using synthetic conduit for Paget –Schroetter Syndrome – a case report and literature...

Article in *Sylwan* · April 2016

CITATIONS

0

READS

183

5 authors, including:



**Patrick Harnarayan**

University of the West Indies, St. Augustine

91 PUBLICATIONS 215 CITATIONS

[SEE PROFILE](#)



**Shariful Islam**

University of the West Indies, St. Augustine

117 PUBLICATIONS 135 CITATIONS

[SEE PROFILE](#)



**Vinoo Bheem**

San Fernando General Teaching Hospital, Trinidad

28 PUBLICATIONS 29 CITATIONS

[SEE PROFILE](#)



**Steve Budhoomam**

Surgimed Clinic

32 PUBLICATIONS 101 CITATIONS

[SEE PROFILE](#)

Some of the authors of this publication are also working on these related projects:



Femoral Hernia in Young male [View project](#)



Diabetic foot infection [View project](#)

## Paraclavicular approach to thoracic decompression with axillary to internal jugular vein bypass using synthetic conduit for Paget –Schroetter Syndrome- a case report and literature review

Patrick Harnarayan<sup>1</sup>, Shariful Islam<sup>2</sup>, Vinoo Bheem<sup>2</sup>, Steve Budhooram<sup>3</sup>, Vijay Naraynsingh<sup>4</sup>

1. University of West Indies, Department of Clinical Sciences, St Augustine, Trinidad & Tobago
2. San Fernando Teaching Hospital, Trinidad and Tobago
3. Surgi-med Clinic, San Fernando, Trinidad and Tobago
4. Medical Associate Hospital, St Joseph, Trinidad and Tobago

### Corresponding author-

Shariful Islam, DM (General surgery), Registrar, Department of Surgery, San Fernando Teaching Hospital, Trinidad & Tobago, [Email-sss1201198@yahoo.com](mailto:Email-sss1201198@yahoo.com), Phone-868-797-4951

### Co-authors-

1. Patrick Harnarayan, FRCS, FACS, Lecturer University of West Indies, St Augustine, Trinidad & Tobago, Email: [patrick\\_harnarayan@hotmail.com](mailto:patrick_harnarayan@hotmail.com)
2. Vinoo Bheem, FRCS, Head of the Department of Surgery (Ag), San Fernando Teaching Hospital, Trinidad & Tobago; Email: [ybheem@hotmail.com](mailto:ybheem@hotmail.com)
3. Steve Budhooram, FRCS, FACS, Specialist Vascular Surgeons, Surgi-med Clinic, San Fernando, Trinidad and Tobago; Email: [stevebud@tstt.net.tt](mailto:stevebud@tstt.net.tt)
4. Professor Vijay Naraynsingh, FRCS, FACS, Professor of Surgery, Medical Associates Hospital, St Joseph, Trinidad and Tobago; Email: [vnaraynsingh@gmail.com](mailto:vnaraynsingh@gmail.com)



## Abstract:

Effort thrombosis of the subclavian vein (Paget –Schroetter Syndrome) is the spontaneous thrombosis of the subclavian-axillary vein usually occurring in patients secondary to excessive or abnormal arm activity, when there is one or more compressive entity at the thoracic inlet.

Treatment involves catheter directed thrombolysis and surgical decompression, usually achieved by first rib resection and venolysis to free the subclavian-axillary vein from fibrous incarceration.

This is best done through the newer paraclavicular approach, which makes use of two incisions, to provide access to ensure the first rib resection and venolysis can be properly achieved. Venous reconstruction by way of a veno-venous bypass may also be required if the thrombus load is significant and this can be augmented by creation of an arterio-venous fistula to increase venous flow (usually sluggish) back to the heart, thereby reducing the risk of venous graft occlusion.

## Introduction:

Paget–Schroetter syndrome or effort thrombosis, also known as Paget–von Schrötter disease, is a form of upper extremity deep vein thrombosis (DVT), a medical condition in which blood clots form in the deep veins of the arms. These DVTs typically occur in the axillary or subclavian veins [1]. Paget (London 1875) and Von-Schroetter (Vienna 1884) had described it independently and Hughes, on reviewing his cases of venous thromboses, coined the name Paget-Schroetter as a result [2]. The condition is relatively rare [3]. It usually presents in young and otherwise healthy patients, and also occurs more often in males than females. We present a case of primary subclavian thrombosis with failed catheter guided thrombolysis and underwent paraclavicular venolysis with resection of the 1<sup>st</sup> rib with axillary vein to internal jugular vein bypass.



**Keywords:** Paget-Schroetter Syndrome, Paraclavicular venolysis, Thrombolysis, Veno-venous bypass

### The Case:

A 47yr old midwife presented with a six day history of a swollen painful right arm. It initially started as a cramping pain of the lower arm with spasm of the forearm muscles and engorgement of entire upper limb veins, resolved after 20 minutes of rest, had now remained swollen and tender with movement limited by pain in the supraclavicular region. She was a well- built midwife of Afro-Caribbean descent, a non-smoker, she was healthy and she had no known medical problems. Her work involved pushing wheelchair-bound pregnant patients along the corridor and helping to lift them unto delivery suite beds prior to their delivery. She was not actively involved in any sporting activities at that time. The patient was previously well until one year ago when she had experienced engorgement of veins on the back of hand after doing household chores and noted pain radiating up to supraclavicular region, both of which resolved after 2-3 days.

She was admitted to the medical unit and a duplex scan was requested of her upper limb which confirmed the clinical suspicion of a right axillary-subclavian vein thrombosis. After chest radiograph, echocardiogram and thrombophilia screen, which were all negative, she was referred to another institution which offered thrombolysis. This was carried out using streptokinase, using the pulse-spray technique with no perioperative problems. However, she had a poor response to the therapy and was referred for open surgical intervention.

On examination, her right upper limb was grossly swollen and oedematous and there was limited movement at the shoulder joint. However, she had a strong radial pulse on this side with good volume and no cyanosis of the fingers. The provocative tests i.e; the Adson's (or the scalene) Test, the Halstead's (costoclavicular) Test and the Hyper abduction Test (of Wright) were positive. A Magnetic Resonance Venography (MRV) of the upper limb and neck showed a near total occlusion of the right proximal subclavian vein (see figure 1, 2). The patient was then prepared for surgical decompression of the thoracic inlet.

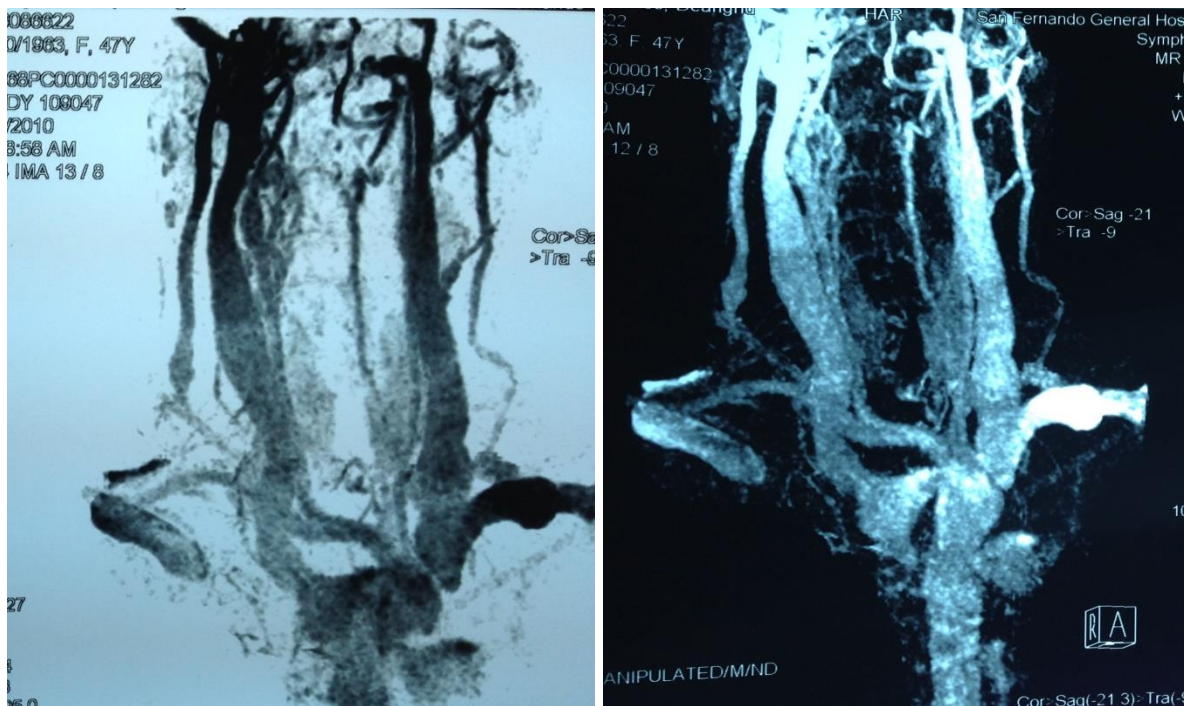
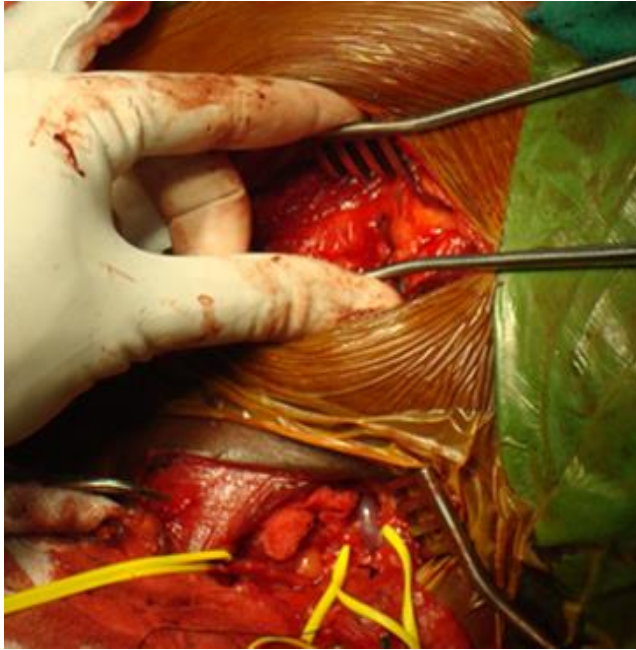

Figure 1, 2: MRV of upper limb, neck showing filling defect in right subclavian vein (see arrow)

## Operative Treatment:

Surgical treatment was planned for the next elective vascular list and patient was consented and prepared for surgery. A paraclavicular approach was chosen to give the best access to the first rib for resection and to allow adequate exposure (figure 3) to the subclavian vein.



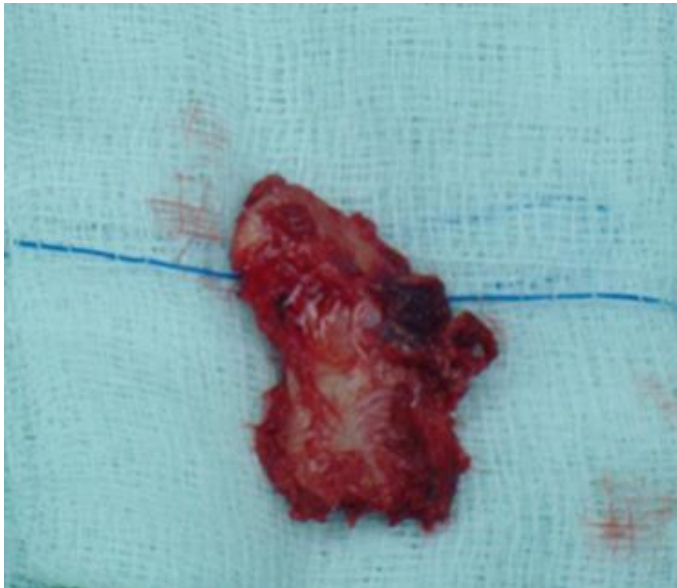*Figure 3: Para-clavicular approach (top-supra, bottom-infra-clavicular incision)*

The para-clavicular approach involves a supraclavicular incision to expose the subclavian vein and free it up from compression by fibrous tissue and an infra-clavicular incision to access the most medial aspect of the first rib and the costo-clavicular space in order to achieve venolysis and thoracic outlet decompression.

The supraclavicular incision was made and the fat pad of scaleneus anterior was dissected and reflected laterally. The scaleneus anterior was isolated and the phrenic nerve was observed running along the edge of this muscle and carefully avoided whilst safely dividing the muscle.

The subclavius muscle lying just below the clavicle was noted to be extremely thick and large in this female subject and needed to be divided and de-bulked to gain access to the first rib. The scalenus anterior is also divided.

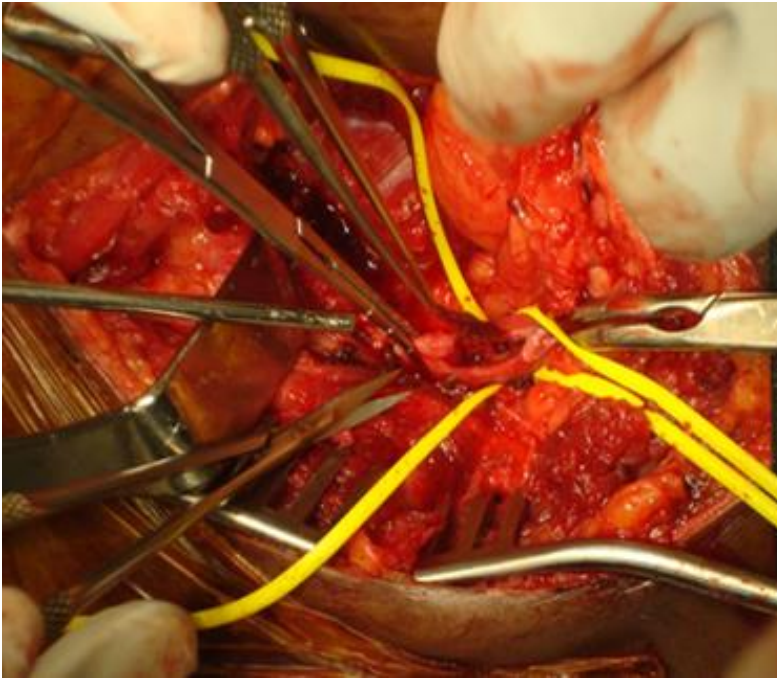
An infra-clavicular incision was then made and the first rib was freed up by blunt and sharp dissection. The anterior aspect of the rib was excised as far medially as the costochondral junction as possible dividing the costo-clavicular ligament as well and the retained edges smoothed to reduce the sharpness (figure 4).



*Figure 4: Resected 1<sup>st</sup> Rib (partial)*

The subclavian vein was noted to be plastered down to the underside of the clavicle by dense scarring, from mid-clavicle to the sternoclavicular joint. Venolysis was then performed to free the subclavian vein up to its junction with the jugular vein. It was palpated as a hard vessel with occluding thrombus and 5000 units of heparin was given intravenously and venotomy was done (figure 5).



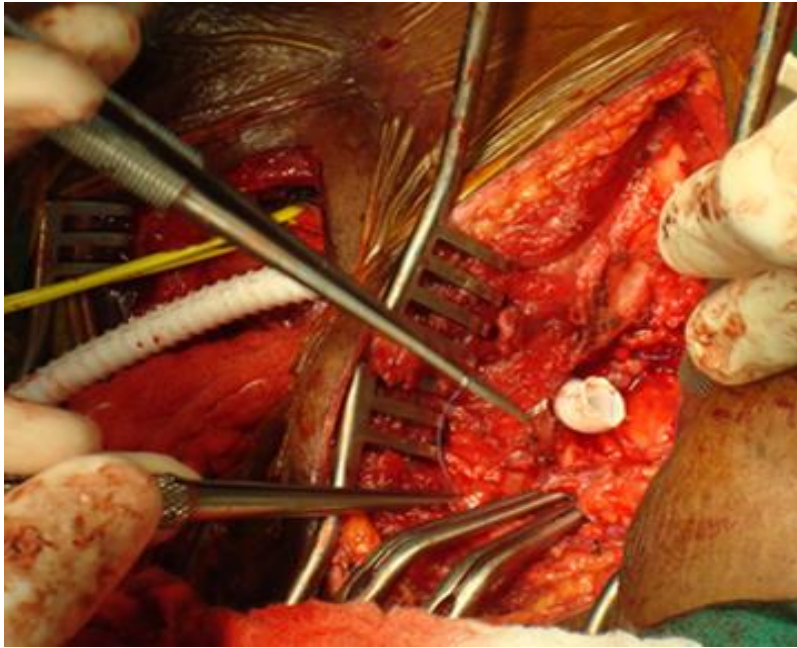


*Figure 5: Venotomy and removal of thrombus from the sub-clavian vein*

Fogarty's catheter (#2 and #3) was passed down the subclavian/axillary vein and organised thrombus was retrieved from as far down as the proximal brachial vein. There was subsequently moderate backflow and after flushing with heparinised saline and a Fogarty #3 embolectomy catheter was also passed down the cephalic vein as it enters the subclavian vein but no clot was extracted.

Due to the dense scarring and thrombus in the proximal subclavian vein indicating only partial thrombolysis, a veno-venous bypass was done from the axillary vein to the internal jugular vein to allow flow to bypass the heavily diseased and thrombosed vessel which was almost totally occluded. The right subclavian and internal jugular veins were isolated and the synthetic conduit, an ePTFE 6mm externally re-enforced graft was used to bypass this vessel from the axillary vein to the internal jugular on the ipsilateral side (figure 6 ).





*Figure 6: Tunnelling of PTFE graft before veno-venous bypass*

An arterio-venous fistula was then created between the (commitantes of) the brachial vein and the brachial artery ( brachio-brachial arterio-venous fistula) to augment flow up the venous systems in order decrease the chance of stasis and new thrombus formation, and therefore augment graft patency rates. At five (5) year of follow up, our patient is still doing well without any further complaints.

### Discussion:

Effort thrombosis (Paget –Schroetter Syndrome) is an uncommon clinical condition seen in the dominant upper limb, usually after a period of unusual exercise or positioning of the arm [4].

Primary upper limb deep vein thrombosis is divided into effort thrombosis (Paget-Schroetter Syndrome) and idiopathic causes and up to 33% of these patients can present with pulmonary embolism [2, 5] as well as severe disabling pain and swelling of all or part of the upper limb.

Secondary causes of upper limb deep vein thrombosis occur in patients with long term indwelling (subclavian) dialysis catheters, patients with pacemakers, hypercoagulable states, malignancies, radiation therapy, trauma and congestive cardiac failure.

The patients who get subclavian- axillary vein thrombosis have occupations or pastimes that usually include excessive, repetitive muscular activity [6] of shoulder, arm, forearm and hand. Jobs such as painting, hair stylists, hospital porters, nurses, bus drivers and sportsmen and women involved in games such as baseball, golf, tennis, squash and weight-lifting have increased chances of thrombosis by virtue of overhead work, especially in a sportsman who may be already dehydrated.

Symptoms may include sudden onset of pain, warmth, redness, blueness and swelling of the arm. Diagnosis is usually confirmed with an ultrasound [7]. These DVTs have the potential to cause pulmonary embolism [8].

The management of effort thrombosis varies widely, and there is no broad consensus as to what constitutes the best approach. The relative rarity of the disease, paucity of information from large randomized trials is factors contributing to this confusion. For many years patients with effort thrombosis were managed conservatively with limb elevation and anticoagulation [9]. However, subsequent long-term data demonstrated an unacceptably high incidence of residual symptoms, disability and recurrent thrombosis with this conservative strategy.

Treatment of axillary-subclavian vein thrombosis has three main goals: removal of the obstructive thrombus, relieving of the extrinsic thoracic compression and treatment via dilatation of any residual intrinsic stenosis [10].

The modern approach to patients with subclavian- axillary vein thrombosis consists of catheter directed thrombolysis followed by anticoagulation, and in selected cases where there are residual symptoms or compression, surgical decompression followed by balloon angioplasty [11].

Since this disease commonly afflicts young and very active individuals, the general consensus is that a staged multimodal approach of thrombolysis, anticoagulation and surgical correction of the underlying anatomical problem will restore venous patency, reduce the incidence of re-thrombosis and allow the patient to return to normal function [11].

Catheter directed thrombolysis and anticoagulation are considered the “first-line therapy” [12] in this disorder. Urokinase is thought to be the most effective agent when locally directed [13] having replaced streptokinase which has been noted to have more systemic side-effects, but problems with its general availability and the presence of genetically engineered tissue plasminogen activator (TPA) led to a decrease in its usage [6].

Thrombolysis is safe and efficient, not only restoring venous patency and reducing symptoms [14] but minimizing endothelial injury thus reducing long term complications such as re-thrombosis. Following thrombolysis, late surgical decompression of the thoracic outlet was the standard of care in many centers [15] however immediate thrombolytic therapy is now followed by early surgical decompression and is considered more effective, safer and the duration of the disability is considerably reduced [16]. This approach means that everything is done in a single hospital visit which, aside from being very practical, appeals to the patient and may be more cost effective in the long run.

The compelling evidence for early surgical therapy following thrombolysis is seen in cases in which lysis is successful, but a venous defect is detected ( two-thirds of the cases) and this can

only be seen on venography (conventional or magnetic resonance venography) with positional changes [17], usually when the arm is in the neutral and then shoulder-abducted positions [2].

The surgical options as far as the incision is concerned vary, with the trans-axillary, supraclavicular, paraclavicular and infraclavicular approaches all being utilized. The paraclavicular approach, considered a “newer” approach has been used extensively in many series [18, 19, 20] and includes a supraclavicular incision which allows access to the first rib and initiates its exposure and resection, as well as infra clavicular incision to complete the anterior first rib resection [12].

The options for surgical decompression aimed at correction of extrinsic vein compression, include first rib resection, anterior and or medius scalenectomy, cervical rib resection and sometimes medial claviculectomy (usually because of callus formation) [6]. This is followed by circumferential venolysis, needed since the severe inflammatory reaction around the vessels; nerve and rib cause the vessels to be incarcerated or plastered down to the rib, as in our patient.

The trans-axillary approach allows for both an open and endoscopic technique and generally, once the extrinsic compression is removed the thrombus lyses spontaneously [2] and the vessel re-canalizes when anticoagulation is started.

First rib resection and scalenectomy (FRRS) has been used in selected patients with subclavian-axillary vein thrombosis who respond to lysis and have demonstrated vein patency, however FFRS with anticoagulation alone has been shown to cause recanalization with improvement of patients’ symptoms [21].

Further surgical options to repair the intrinsic vein defect include thrombus extraction using balloon catheter thrombectomy [12] and balloon angioplasty with or without vein patching [22, 23] indicated if there is a question of patency of the vessel and if the thrombus load is significant.

There may be a need for a venous bypass if there is incomplete or minimal thrombus dissolution following thrombolysis. This can be done by way of a cephalic vein crossover bypass [24], internal jugular vein “turndown” [13] or less commonly, a veno-venous bypass (as in our patient) [25]. Thus the range of venous intervention to restore normal venous patency includes circumferential venolysis, balloon thrombectomy, vein patch angioplasty and endovenectomy or internal jugular transposition.

In order to diminish the chance of new thrombosis formation and thus occlusion of this venous bypass (as in direct contradistinction to an arterial bypass from a high flow, high pressure system), the initial sluggish venous flow through the constructed bypass can be enhanced by creating an arterio-venous fistula [24, 26]. This can be done at the level of wrist (radio-cephalic fistula) [27] or at the antecubital fossa (brachio-cephalic or brachio-brachial fistula) and it increases return flow through the graft, especially during the first 24-48 hours post-surgery when the system is thought to be at most risk of thrombus formation and until the intimal healing of the subject vessel occurs [28]. This was done in our patient and we favoured a brachio-brachial fistula with a small bore which we thought would likely self-occlude after 2-3 months. This was an important adjunct since poor functional outcome is usually seen in occluded venous repairs which have extensive venous thrombosis [22].

Endovascular intervention can be utilized after successful thrombolysis at the time of surgical decompression by way of transluminal angioplasty [23, 28] but the use of endovascular intervention preoperatively was found to be of no benefit in patency rates postoperatively [29].

The use of endogenous stenting usually fails due to persistent thrombosis, further complicating the initial management [18]. In one series, all the patients who had intravenous stenting re-occluded their vessels as early as day one (1) to six (6) weeks after stent placement [30]. In the absence of surgical decompression and angioplasty, stenting is not advisable [31] and it is considered prudent to generally avoid use of stents [23, 30] in the management of these patients.

### Conclusion:

Paget-Schroetter syndrome is a relatively uncommon disease seen in young active, otherwise healthy individuals. Compression and repetitive injury of the subclavian- axillary vein initiates the thrombosis and management involves early catheter-directed thrombolysis, immediate paraclavicular thoracic decompression and venous reconstruction [32]. Removal of the first (1<sup>st</sup>) rib will decompress the subclavian-axillary vein and although lysis restores patency, rib resection is necessary to relieve external compression. Venous thrombectomy may be required if the thrombus load is large and if is not completely dissolved by thrombolytic therapy as is usually the case. If the above measures fail to restore patency a veno-venous bypass using synthetic graft can be a viable option like our case. An arterio-venous fistula can also be created to enhance the chance of prolonged graft patency by increasing flow back to the heart and hence reducing risk of graft thrombosis.

### Acknowledgement

Informed consent was obtained from patient to publish this case.

### Disclosure

The authors have nothing to disclose.

### Conflicts of interest

There is no conflict of interest among the authors in publication of this case report



## References:

1. Hughes, E. S. R. (1949-02-01); "Venous obstruction in the upper extremity; Paget-Schroetter's syndrome; a review of 320 cases". *Surgery, Gynecology & Obstetrics* 88 (2): 89–27. ISSN 0039-6087. PMID 18108679
2. Viju Vijaysadan, MD, Aphrodite M. Zimmerman, MS, Rafael E. Pajaro, MD; Paget-Schroetter Syndrome in the Young and Active *J Am Board Fam Med.* 2005; 18(4):314
3. Hughes, ES (1949); "Venous obstruction in the upper extremity; Paget–Schroetter's syndrome; a review of 320 cases". *Surg Gynecol Obstet* 88 (2): 89–27; PMID 18108679.
4. Rutherford RB. Primary subclavian-axillary vein thrombosis: the relative roles of thrombolysis, percutaneous angioplasty, stents, and surgery. *Semin Vasc Surg.* 1998 Jun; 11(2):91-5.
5. Ameli FM, Minas T, Weiss M, Provan JL, Consequences of "conservative" conventional management of axillary vein thrombosis. *Can J Surg.* 1987 May; 30(3):167-9?
6. Urschel HC Jr1, Razzuk MA, Paget-Schroetter syndrome: what is the best management? *Ann Thorac Surg.* 2000 Jun; 69(6):1663-8; discussion 1668-9.
7. Di Nisio, M.; Van Sluis, G. L.; Bossuyt, P. M. M.; Büller, H. R.; Porreca, E.; Rutjes, A. W. S. (2010-04-01). "Accuracy of diagnostic tests for clinically suspected upper extremity deep vein thrombosis: a systematic review". *Journal of thrombosis and haemostasis: JTH* 8 (4): 684–692. doi:10.1111/j.1538-7836.2010.03771.x. ISSN 1538-7836. PMID 20141579.

8. Mai, Cuc; Hunt, Daniel (2011-05-01). "Upper-extremity deep venous thrombosis: a review". *The American Journal of Medicine* 124 (5): 402–407. doi:10.1016/j.amjmed.2010.11.022; ISSN 1555-7162; PMID 21531227.
9. Kearon, Clive; Akl, Elie A.; Comerota, Anthony J.; Prandoni, Paolo; Bounameaux, Henri; Goldhaber, Samuel Z.; Nelson, Michael E.; Wells, Philip S.; Gould, Michael K. (2012-02-01). "Antithrombotic therapy for VTE disease: Antithrombotic Therapy and Prevention of Thrombosis, 9th Ed: American College of Chest Physicians Evidence-Based Clinical Practice Guidelines". *Chest* 141 (2 Suppl): e419S–94S; doi:10.1378/chest.11-2301; ISSN 1931-3543. PMC 3278049; PMID 22315268
10. Sanders RJ1, Hammond SL. Venous thoracic outlet syndrome. *Hand Clin.* 2004 Feb; 20(1): 113-8.
11. Kunkel JM1, Machleder HI; Treatment of Paget-Schroetter syndrome, A staged multi-disciplinary approach, *Arch Surg.* 1989 Oct; 124(10):1153-79. Machleder HI. Evaluation of a new treatment strategy for Paget-Schroetter syndrome: spontaneous thrombosis of the axillary-subclavian vein. *J Vasc Surg.* 1993 Feb; 17(2):305-15; discussion 316-7.
12. Roche-Nagle G1, Ryan R, Barry M, Brophy D. Effort thrombosis of the upper extremity in a young sportsman: Paget-Schroetter syndrome. *Br J Sports Med.* 2007 Aug; 41(8):540-1; discussion 541. Epub 2007 Feb 8.
13. Machleder HI. Effort thrombosis of the axillo-subclavian vein: a disabling vascular disorder. *Compr Ther.* 1991 May; 17(5):18-24.

14. Sheeran SR1, Hallisey MJ, Murphy TP, Faberman RS, Sherman S, Local thrombolytic therapy as part of a multi-disciplinary approach to acute axillo-subclavian vein thrombosis (Paget-Schroetter syndrome); *J Vasc Interventional Radiology*. 1997 Mar-Apr; 8(2):253-60.
15. Angle N1, Gelabert HA, Farooq MM, Ahn SS, Caswell DR, Freischlag JA, Machleder HI. Safety and efficacy of early surgical decompression of the thoracic outlet for Paget-Schroetter syndrome, *Ann Vasc Surg*. 2001 Jan; 15(1):37-42.
16. Caparrelli DJ1, Freischlag J.A unified approach to axillo-subclavian venous thrombosis in a single hospital admission. *Semin Vasc Surg*. 2005 Sep; 18(3):153-7.
17. Bandyk DF, Modern treatment of Axillary Subclavian vein DVT; Veith conference 2003. New York.
18. Urschel HC Jr1, Patel AN Surgery remains the most effective treatment for Paget-Schroetter syndrome: 50 years' experience. *Ann Thoracic Surgery*, 2008 Jul; 86(1):254-60; discussion 260. Doi: 10.1016/j.athoracsur.2008.03.021.
19. Desaii SS, Toliyat M, Dua A, Charlton-Ouw KM, Hossain M, Estrera AL, Safi HJ, Azizzadeh A. Outcomes of Surgical Paraclavicular Thoracic Outlet Decompression. *Ann Vasc Surg* 2014 Feb; 28(2):457-64. Epub 2013 Dec 28
20. Thompson RW1, Schneider PA, Nelken NA, Skioldebrand CG, Stoney RJ, Circumferential venolysis and paraclavicular thoracic outlet decompression for "effort thrombosis" of the subclavian vein. *J Vasc Surg*. 1992 Nov; 16(5):723-32

21. de León R1, Chang DC, Busse C, Call D, Freischlag JA. First rib resection and scalenectomy for chronically occluded subclavian veins: what does it really do? *Ann Vasc Surg.* 2008 May. - Jun; 22(3):395-401.
22. Schmacht DC1, Back MR, Novotney ML, Johnson BL, Bandyk DF. Primary axillary-subclavian venous thrombosis: is aggressive surgical intervention justified? *Vasc Surg.* 2001 Sep-Oct; 35(5):353-9.
23. Schneider DB<sup>1</sup>, Dimuzio PJ, Martin ND, Gordon RL, Wilson MW, Laberge JM, Kerlan RK, Eichler CM, Messina LM. Combination treatment of venous thoracic outlet syndrome: open surgical decompression and intraoperative angioplasty. *J Vasc Surg.* 2004 Oct; 40(4):599-
24. Hashmonai M, Schramek A, Farbstein J. Cephalic vein cross-over bypass for subclavian vein thrombosis: a case report. *Surgery* 1976 Nov; 80(5):563-4.
25. Kreidy R1, Abdelnour E. Brachial to internal jugular vein bypass, a case report. *J Med Liban.* 1998 Jul-Aug; 46(4):222-6.
26. Johnson V, Eiseman B Evaluation of arterio-venous shunt to maintain patency of venous auto-graft. *Am J Surg* 1969; 118: 915-2.
27. Puskas JD1, Gertler JP, Internal jugular to axillary vein bypass for subclavian vein thrombosis in the setting of brachial arterio-venous fistula. *J Vasc Surg.* 1994 May; 19(5):939-42.
28. Cancer S, Luján S, Puras E. Intra-operative venous balloon angioplasty during surgical thoracic outlet decompression in Paget-Schrötter syndrome, *Vascular* 2004 Mar; 12(2):136-

29. Guzzo JL, Chang K, Demos J, Black JH, Freischlag JA. Preoperative thrombolysis and venoplasty affords no benefit in patency following first rib resection and scalenectomy for subacute and chronic subclavian vein thrombosis. *J Vasc Surg.* 2010 Sep; 52(3):658-62; discussion 662-3. Doi: 10.1016/j.jvs.2010.04.050.
30. Urschel HC Jr1, Patel AN. Paget-Schroetter syndrome therapy: failure of intravenous stents. *Ann Thorac Surg.* 2003 Jun; 75(6):1693-6; discussion 1696.
31. Landry GJ1, Liem TK Endovascular management of Paget-Schroetter syndrome. *Vascular* 2007 Sep-Oct; 15(5):290-6.
32. Thompson RW, Comprehensive management of subclavian vein effort thrombosis. *Semin Intervent Radiology* 2012 Mar; 29(1):44-51. Doi: 10.1055/s-0032-1302451.

