

See discussions, stats, and author profiles for this publication at: <https://www.researchgate.net/publication/317598359>

# IMMEDIATE LATISSIMUS DORSI MYOCUTANEOUS FLAP RECONSTRUCTION IN GIANT PHYLLODES TUMOR OF BREAST– A REPORT OF TWO CASES WITH LITERATURE REVIEW

Article in *Sylwan* · June 2017

CITATIONS  
0

READS  
315

5 authors, including:



**Shariful Islam**

University of the West Indies, St. Augustine

117 PUBLICATIONS 135 CITATIONS

SEE PROFILE



**Patrick Harnarayan**

University of the West Indies, St. Augustine

91 PUBLICATIONS 215 CITATIONS

SEE PROFILE



**Vinoo Bheem**

San Fernando General Teaching Hospital , Trinidad

28 PUBLICATIONS 29 CITATIONS

SEE PROFILE



**Vijay Naraynsingh**

Medical Associates

336 PUBLICATIONS 1,726 CITATIONS

SEE PROFILE

Some of the authors of this publication are also working on these related projects:



Non antibiotic management of acute uncomplicated diverticulitis [View project](#)



Reconstructive surgery [View project](#)

## IMMEDIATE LATISSIMUS DORSI MYOCUTANEOUS FLAP RECONSTRUCTION IN GIANT PHYLLODES TUMOR OF BREAST– A REPORT OF TWO CASES WITH LITERATURE REVIEW

*Islam S<sup>1</sup>, Shah J<sup>2</sup>, Harnarayan P<sup>2</sup>, Bheem V<sup>1</sup>, Naraynsingh V<sup>2</sup>*

1. Department of Surgery, San Fernando Teaching Hospital, Trinidad & Tobago

2. Department of Clinical Surgical Sciences, University of the West Indies, St Augustine, Trinidad and Tobago

### Corresponding Author:

Dr. Shariful Islam, MBBS, DM (Surgery), Associate Lecturer, Department of Clinical surgical Sciences, University of the West Indies, St Augustine, Trinidad and Tobago

Registrar in General Surgery, San Fernando Teaching Hospital, Trinidad & Tobago, Phone-868-797-4951, email: [sssl201198@yahoo.com](mailto:sssl201198@yahoo.com) /[shar\\_islam7@hotmail.com](mailto:shar_islam7@hotmail.com)

### Highlights for Review:

- The diagnosis of phyllodes tumor should be entertained in all patients presenting with a rapidly increasing breast lump
- Emphasis should be made for early diagnosis and treatment to decrease future morbidity and mortality
- Core needle biopsy is the key method of preoperative diagnosis of phyllodes tumor
- Immediate chest wall reconstruction can be performed in all patients, even with phyllodes tumors greater than 20 cm
- Immediate reconstruction offers a unique psychological advantage compare to delayed.
- Latissimus dorsi myocutaneous flap can be used successfully with minimal donor site morbidity and improved cosmetic outcome.



### Abstract:

Phyllodes tumors are rare, accounting for less than 1% of all breast neoplasms. Giant Phyllodes (tumor greater than 10 cm) are even rarer. Delayed presentation leads to a locally advanced disease, with surgeons often finding it difficult to cover the ensuing chest wall defect. Only two cases of giant phyllodes tumors comparable to our patients' size are reported in the literature (in which immediate flap closure was performed). We report the third and fourth cases of giant phyllodes tumors greater than 30 cm in which immediate latissimus dorsi myocutaneous flap reconstruction was successfully performed after mastectomy.

### Introduction:

Phyllodes tumors are rare fibro-epithelial lesions. They make up 0.3 to 0.5% of female breast tumors and have an incidence of about 2.1 per million (Rowell '93) <sup>1</sup>. Accurate preoperative diagnosis and proper management are crucial in phyllodes tumors. The local recurrence rate is 4% for benign phyllodes tumors<sup>2</sup>, but for malignant phyllodes tumors the local recurrence rate approaches 10- 16.1% <sup>1</sup> and the distant metastases rate is 6.3 to 31% <sup>3,4</sup>.

Although many large tumors have been documented in the English literature, few cases of giant phyllodes tumor (comparable to our patients' size), report the use of latissimus dorsi flaps to cover a large defect. Emphasis should be made for early diagnosis and intervention to decrease morbidity and mortality.

**Key words:** Benign giant phyllodes tumor, malignant giant phyllodes tumor, immediate breast reconstruction, Latissimus dorsi (LD) flap

### Case Report 1:

A 44 year old Indo-Trinidadian female was referred to our Breast Clinic with a 50x50 cm mass in her right breast. On examination the patient was emaciated / malnourished and anemic with a fungating mass (approximately 50x50 cm) occupying the entire right chest wall, with prominent



dilated blood vessels (figure 1). The patient had palpable right axillary lymph nodes and her left breast examination was normal. Needle core biopsy revealed a benign phyllodes tumor with extremes infarction. A CT scan of the chest revealed a heterogeneous enhancing mass in the right breast with an ill-defined deep margin at the RUOQ. Few enlarged axillary lymph nodes with no suspicious features were noted, and there were no obvious chest wall or pulmonary metastases (figure 2). CT abdomen and pelvis showed no liver or bony metastases. Right wide mastectomy with partial excision of pectoralis major, axillary lymph node sampling (figure 3) and immediate latissimus dorsi (LD) flap closure (figure 4) was performed. The patient had a successful postop recovery (figure 5).

Histology of the specimen revealed a low grade (benign) phyllodes tumor with scanty mitoses and minimal nuclear atypia. Six (6) axillary lymph nodes were identified with reactive changes and no metastasis. All resection margins were otherwise negative. The case was discussed at our MDT meeting and a decision made for long term follow up with no adjuvant therapy. After several months, the patient was readmitted with a massive pleural effusion on the contra-lateral side of the tumor. Cytology of the pleural fluid revealed malignant cells. The original histopathology of the specimen was once again reviewed by two senior pathologists, but failed to diagnose any malignancy. Despite further treatment patient demised after 6 months from her initial surgery.

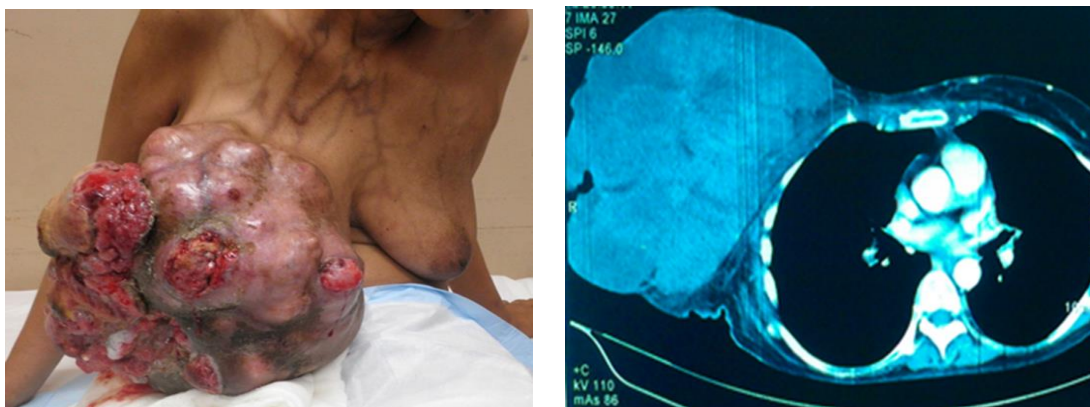


Figure 1 Giant phyllodes tumor with prominent dilated subcutaneous vessels; Figure 2 CT chest showing heterogeneous enhancing mass in right breast with ill-defined deep margin



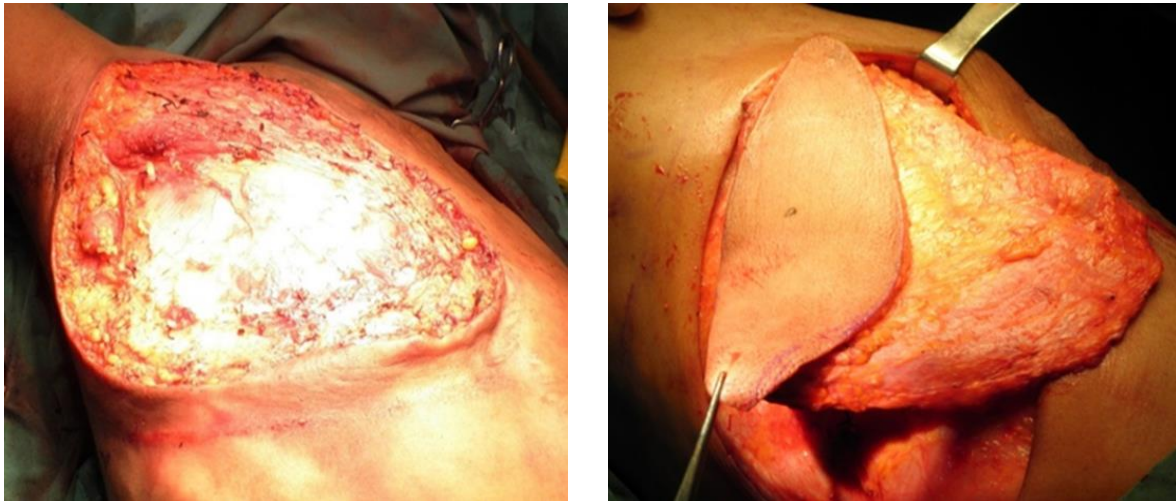

Figure 3: Chest wall after excision of phyllodes tumor; Figure 4: Latissimus Dorsi flap to cover the anterior chest wall

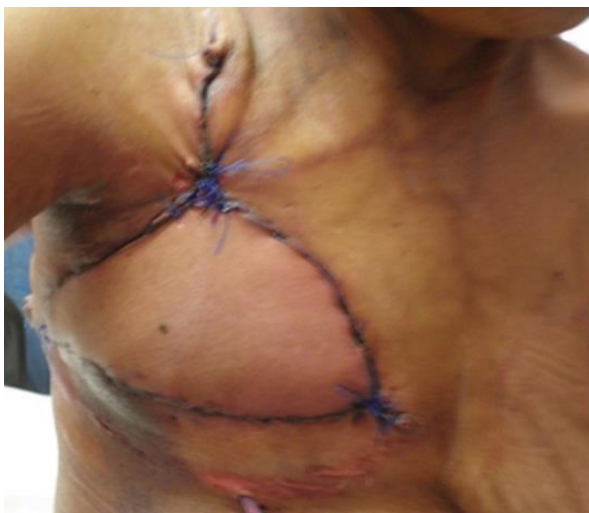

Figure 5: Photograph taken on postop follow up

### Case 2:

A 46 year old Indo –Trinidadian female patient presented with a large right breast lump for 6 months, with no family history of breast or ovarian cancer. On examination the mass was 20x18 cm in size with no palpable axillary lymph nodes. The patient was advised on further radiological investigation as well as needle core biopsy to confirm the diagnosis of giant



phyllodes tumor, and mastectomy proposed. The patient defaulted from the clinic and returned after 6 months. She revealed that she sought help from alternative medicine, but it did not work for her. On examination of her right breast the mass was 34 x 24 cm with obvious skin induration and peau d'orange (figure 6) however there were no palpable axillary lymph nodes. A needle core biopsy revealed benign phyllodes tumor. CT scan of the chest and abdomen revealed no pulmonary or liver metastases. Subsequently the patient underwent wide mastectomy (figure 7) with immediate latissimus dorsi myocutaneous flap reconstruction (figure 8). The patient had a successful post op recovery (figure 8). Final histology revealed a benign phyllodes tumor with few mitoses and scanty nuclear pleomorphism. At 3 years follow up the patient remains symptom-free and there is no sign of local recurrence or distal metastasis.

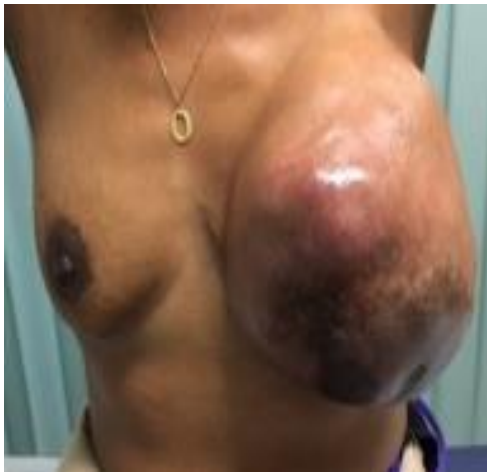

Figure 6: Giant phyllodes tumor

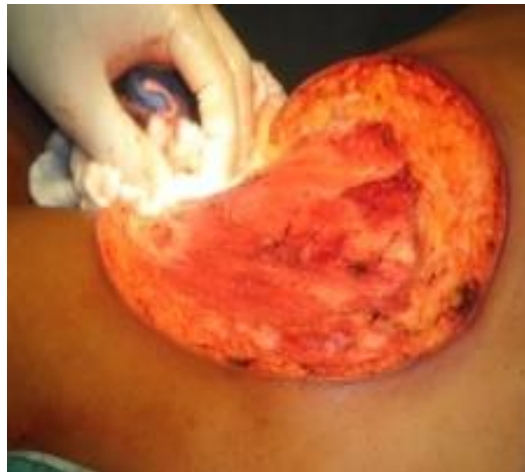

Figure 7: Chest wall after excision of giant phyllodes



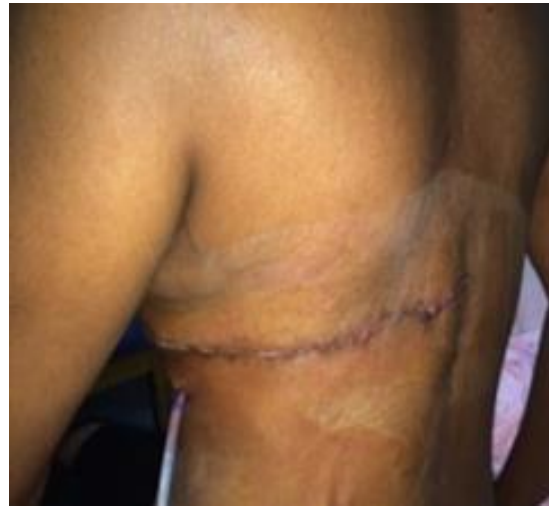
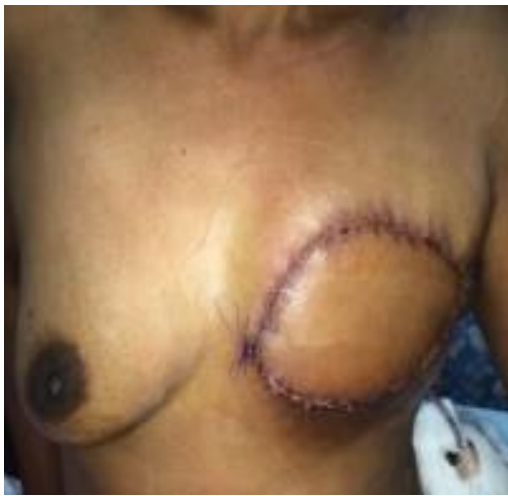
Figure 8: Closure of chest wall defect with LD myocutaneous flap Figure 9: Scar on the back after LD myocutaneous flap removal

#### Discussion:

Phyllodes tumor was first described by Chelius in 1827<sup>5</sup>. The term cysto-sarcoma phyllodes was coined by Johannes Muller in 1838. This tumor was believed to be benign until 1943, when Cooper and Ackerman reported on its malignant biological potential.

The World Health Organization adopted the term phyllodes tumor in 1981; as described by Rosen et al in 2001. He sub-classified them into benign, borderline, or malignant according to the features such as tumor margins, tumor necrosis, stromal overgrowth, cellular atypia, and number of mitoses per high power field<sup>6</sup>.

Approximately 85-90% of phyllodes tumors are benign and 10-15% malignant<sup>7</sup>. Although the benign tumors do not metastasize, there is a strong tendency for aggressive growth and local recurrence<sup>8</sup>.

The median size of phyllodes tumors is 4cm; however, < 10% of tumors grows larger than 10 cm and these have been defined as giant phyllodes tumor. Very rarely they can be up to 50 cm in diameter. In recent years, several giant phyllodes tumor have been reported<sup>9-17</sup>.



In 10-15% cases axillary lymph nodes are palpable but <1% had pathologically positive nodes. There are no pathognomonic mammographic or ultrasound features of phyllodes tumor<sup>18</sup>. Core tissue biopsy is the preferred method of pre-operative diagnosis.

Surgical management depends on both the size of the phyllodes tumor and size of the breast. Wide local excision can be done for smaller tumors<sup>11</sup>; however mastectomy should be reserved for larger tumors > 10 cm<sup>19,20</sup> and should be considered in recurrent and malignant tumors<sup>21,22</sup>. Most experts currently advocate at least 1 cm resection margins on primary excision or re-excision of a tumor, as long as the tumor-to-breast size will permit<sup>21-24</sup>.

Dissection of these giant tumors can often be very tedious. Studies have shown that most of these giant tumors receive their blood supply from the hugely dilated cutaneous blood vessels. Therefore surgeons need to be very meticulous in order to avoid any major blood loss.

Finally, closure of the potentially huge chest wall defect after excision of giant phyllodes tumors, as in our patients, still remains a great challenge for the surgeons.

There is no absolute contraindication for immediate chest wall reconstruction after mastectomy in cases of giant phyllodes tumor. However, the form of reconstruction will depend on the patient preference and the availability of expert personnel<sup>25</sup>.

Our first patient presented with one of the largest giant phyllodes tumor ever recorded in the English literature, measuring 50 x 50cm. It was fungating, fixed to the skin, but mobile over the underlying muscle and her axillary lymph nodes were palpable. There were multiple hugely dilated feeding blood vessels to the tumor, which can be challenging surgically and have to be identified (especially subcutaneous veins and perforating intercostal vessels). Similarly, our second patient also presented with a giant phylloides measuring 34x 24 cm.

There are different methods of closure of the chest wound. Options include primary closure with advancement flap<sup>13,20</sup> and if unsuitable, VAC closure or marlex mesh closure with delayed cover, with either split thickness skin graft<sup>12</sup> or pedicle flap closure (either Latissimus dorsi myocutaneous or fascio cutaneous flap or Transverse rectus abdominis myocutaneous flap<sup>22</sup>).





The Marlex mesh and the Latissimus dorsi muscular/myocutaneous flap are the two most commonly recommended methods for reconstruction of the chest wall<sup>12,23,26</sup>.

Chest wall reconstruction can be either immediate or delayed. Immediate reconstruction has its unique psychological advantage over the delayed reconstruction. It can be performed with an implant<sup>27,28</sup> or implant plus AlloDerm<sup>29</sup>, marlex mesh or pedicle flaps<sup>12,24,25</sup>. Pedicle flap closure can be either immediate or delayed using either Latissimus dorsi myocutaneous or fascio-cutaneous flap or Transverse rectus abdominis myocutaneous flap.

In 2008, Singh et al published a series of seven patients' in whom immediate breast reconstruction was performed with latissimus dorsi (LD) myocutaneous flap in 4 patients and transverse rectus abdominis myocutaneous (TRAM) flap in 3 patients<sup>19</sup>. However, all these tumors were less than 20 cm.

The use of latissimus dorsi (LD) myocutaneous flap in giant phyllodes tumor over 20 cm was first reported in 2011 by Romesh Sarvanandan et al (40x35)<sup>10</sup> and by Tarun et al (50 x 20 x 20 cm)<sup>17</sup>. Our first patient had a phyllodes tumor of 50 x50 cm and it was 34 x 24 cm in our second patient. Immediate chest wall reconstruction was performed successfully in both patient using latissimus dorsi myo-cutaneous flaps.

The latissimus dorsi (LD) flap was first utilized in the 1970's. The thoracodorsal artery is the main vascular supply to the flap. It can be lifted off the back either as a muscle flap alone or as myocutaneous flap. The pedicle flap is then brought around to the front of the chest wall without twisting its blood supply.

It is commonly combined with a tissue expander or an implant. This gives the surgeon better control over the aesthetic appearance of the breast. It provides a source of soft tissue that allows complete coverage of an underlying implant. Compared to an implant alone, it helps to create a more natural looking breast shape. However, it is associated with a higher chance of having a second operation<sup>30</sup>.



Rarely, it can be the primary reconstruction method without the need for an implant, especially for thin patients with a small breast volume, as in ours. It can also be used as a backup plan in patients with soft tissue failure or poor wound healing in the setting of an implant. Similarly, it may be a salvage procedure in patients who are not fit for other autogenous procedures or has history of previous chest wall radiation. Finally, it can also be used to cover a large defect on the chest wall in those patients who requires chest wall reconstruction alone, without the need for creation of a breast shape. In both of our cases, the LD flap was used simply to cover the large chest wall defect.

LD flap is contraindicated in patients who do not want additional scarring on their body or have had previous thoracotomy or who participate in extreme competitive sports such as swimming, mountain climbing and skiing.

The added postoperative complications of this procedure other than those seen in traditional mastectomy are due to the donor site morbidity. Tomita K et al, observed that obesity, increased patient age and breast surgery for invasive cancers are risk factors for donor-site seroma formation after breast reconstruction with the latissimus dorsi flap<sup>31</sup>.

Secondary procedures i.e nipple-areola reconstruction, expander implant exchange, adjustment procedures to improve breast symmetry, if needed after an LD flap reconstruction, can be performed in about three months. However, any additional surgery should be put on hold until chemotherapy is completed.

Patients usually experience no major physical limitations from removing the latissimus dorsi muscle. Daily activities and most exercise can be started without any significant loss of proficiency<sup>32</sup>.

### Conclusion:

Mastectomy is the preferred choice for complete excision of a giant phyllodes tumor to prevent local recurrence. Closure of the chest wall defect after mastectomy is often a great challenge. Immediate closure with reconstruction has greater psychological advantage over delayed



reconstruction. Latissimus dorsi myocutaneous flap procedure offers a unique advantage to cover such defects, with a low risk of flap necrosis or donor-site morbidity. It provides good cosmetic outcome and can be used successfully in high risk patients who are not suitable for either TRAM or DIEP flap.

**Conflicts of Interest:** The authors have no conflicts of interest amongst themselves in publishing this case report.

**Author's disclosure:** The authors have nothing to disclose.

**Patient Consent:** Patient consent was obtained for publication of these case reports.

#### References:

1. Rowell M. D, R. R. Perry, J. G. Hsiu, and S. C. Barranco, "Phyllodes tumors," *The American Journal of Surgery*, vol. 165, no. 3, pp. 376–379, 1993.
2. Salvadori B, Cusumano F, Del Bo R, Delledonne V, Grassi M, Rovini D, et al.: Surgical treatment of phyllodes tumors of the breast. *Cancer* 1989, 63:2532-36.
3. Wei J; Tan YT; Cai YC; Yuan ZY; Yang D; Wang SS; Peng RJ; Teng XY; Liu DG; Shi YX, Predictive factors for the local recurrence and distant metastasis of phyllodes tumors of the breast: a retrospective analysis of 192 cases at a single center. *Chin J Cancer*. 2014; 33(10):492-500 (ISSN: 1000-467X)
4. Chaney AW, Pollack A, Mc Neese MD, Zagars GK: Adjuvant radiotherapy for phyllodes tumor of breast. *Radiat Oncol Investig* 1998, 6:289-90.
5. Chelius M, *Neue Jahrbucher Der Teutschen Medicin and Chirurgie*, Naegele und Puchelt, Heidelberg, Germany, 1827.
6. Rosen P. P, *Rosen's Breast Pathology*, Lippincott William Wikins, New York, NY, USA, 2nd edition, 2001.



7. Jones AM, Mitter R, Poulson R, et al. mRNA expression profiling of phyllodes tumors of the breast: identification of genes important in the development of borderline and malignant phyllodes tumors. *Journal of Pathology*, Dec 2008; 216(4):408-17.
8. Noguchi S, Motomura K, Inaji H, Imaoka S, Koyama H: Clonal analysis of fibroadenoma and phyllodes tumor of the breast. *Cancer Res* 1993, 53:4071-74.
9. Juliana Alves De Suza, Elvira Ferreira Marques, Camilla Guatelli, Deise Santiago Girao, Thiago Queroz, Luciana Graziano et al, Malignant phyllodes tumor of the breast: case report, *IMAGEM EM MEDICINA* 2011
10. Ramesh Sarvanandan, Ramesh Thangaratnam, AJ Chen Leong; Immediate Latissimus dorsi pedicle flap reconstruction following the removal of an eight kilogram giant phyllodes tumor of the breast: a case report, *Journal of Medical Case Reports* 2011, 5:44
11. Junaid Nabi, S. M. Quamrul Akhter and Fatema N. Anthony; A case of large phyllodes tumor causing ruptures of the breast: A unique presentation; *Case report in Oncological Medicine*, volume 2013, Article ID 871292, 4 pages
12. Mohammed A. Sbeih, Ryan Engdahl, Marina Landa, Oreoluwa Ojutiku, Norman Morrison, Hector Depaz, -A giant phyllodes tumor causing ulceration and severe breast disfigurement: case report and review of giant phyllodes, *Journal of Surgical Case Reports*, 2015, 12, 1-4
13. Tapanutt Likhitmaskul, Wichitra Asanprakit, Sivinee Charoenthammaraksa, Visnu Lohsiriwat, Surapong Supaporn, Wichai Vassanasiri et al, Giant benign phyllodes tumor with lactation changes in pregnancy: a case report; *Gland Surgery* 2015; 4(4):339-343
14. Dong Xia, Huaiquan Zuo, Yi Quan, Hongliang Dong, Liang Xu, Giant phyllodes tumor of the breast: a case report. *The Chinese-German Journal of Clinical Oncology*, November 2010, Volume 9, Issue 11, pp 674-676
15. Rumi Khajotia, Sangeetha Poovaneswaran, Thamilselvam Pavadai, Subathra Sabaratnam, Hanizah Khairan; Unusually large breast tumor in a middle-aged woman, *Can Fam Physician* 2014;60:142-6 Vol 60: february 2014
16. Banno A1, Shimada A1, Aga K1, Harada H1, Kaburagi T1, Seki H1, Yasui N1, Matsumoto H1. Total mastectomy and chest reconstruction for a rapidly progressing giant



- phyllodes tumor with skin necrosis: a case report. *Surg Case Rep.* 2015 Sep 14; 1:82. e Collection 2015.
17. Tarun Kumar, Mahesh D. Patel, Rexeena Bhargavan, Prabhat Kumar, Mahesh H. Patel, Kiran Kothari et al. Largest phyllodes tumor- case report and brief review article, *Indian J Surg Oncol* (April-June 2011) 2(2): 141-144; DOI 10.1007/s13193-011-0077-3
  18. Cole-Beuglet C, Soriano R, Kurtz AB, Meyer JF, Kopans DB, Goldberg BB: Ultrasound, x-ray mammography, and histopathology of cysto-sarcoma phyllodes. *Radiology* 1983, 146:481-86.
  19. Singh G, Sharma RK: Immediate breast reconstruction for phyllodes tumors. *The Breast* 2008, 17:296-231.
  20. Liang MI, Ramaswami B, Patterson CC, McKelvey MT, Gordillo G, Nuova GJ, Carson WE: Giant breast tumors: surgical management of phyllodes tumors, potential for reconstructive surgery and a review of literature. *World J Surg Oncol* 2008, 6:117, doi: 10.1186/1477-7819-6-117 PMID: PMC2648962
  21. Fentiman IS, Hamed H: Breast reconstruction. *Int J Clin Pract* 2006, 60:471-474.
  22. Likhitmaskul T, Asanprakit W, Charoenthammaraksa S, Lohsiriwat V, Supaporn S, Vassanasiri W, Sattaporn S. Giant benign phyllodes tumor with lactating changes in pregnancy: a case report. *Gland Surg* 2015; 4(4):339-343. doi:10.3978/j.issn.2227-684X.2015.01.09
  23. Walravens C, De Greef C: Giant phyllodes tumor of the breast. *J Plast Reconstr Aesthet Surg* 2008, 61:e9-e11.
  24. Hsu SD1, Chou SJ, Hsieh HF, Chen TW, Cheng MF, Yu JC. Giant malignant mammary phyllodes tumor: report of a case and review of the literature. *Onkologie.* 2007 Feb; 30(1-2):45-7. Epub 2007 Jan 26.
  25. Mangi A. A, B. L. Smith, M. A. Gadd, K. K. Tanabe, M. J. Ott, and W.W. Souba, "Surgical management of phyllodes tumors," *Archives of Surgery*, vol.134, no.5, pp. 487-493, 1999.
  26. Hammond DC: Post-mastectomy reconstruction of the breast using the LD musculo-cutaneous flap. *Cancer J* 2008, 14:248.



27. Mendel M. A, R. G. De Palma, C. Vogt, and J. W. Reagan, "Cysto-sarcoma phyllodes: treatment by subcutaneous mastectomy with immediate prosthetic implantation," *The American Journal of Surgery*, vol. 23, pp. 718–721, 1972
28. Orenstein A, Tsur H: Cysto-sarcoma phyllodes treated by excision and immediate reconstruction with silicone implant. *Ann Plast Surg* 1987, 18:520-23.
29. Shirley A Crenshaw, Michael D Rollerand Jeffery K Chapman. Immediate breast reconstruction with a saline implant and AlloDerm, following removal of a Phyllodes tumor; Published online 2011 Mar 21. doi: 10.1186/1477-7819-9-34 PMID: PMC3070675
30. M.K. Roy, S. Shrotia, C. Holcombe, D.J.T. Webster, L.E. Hughes, R.E. Mansel. Complications of latissimus dorsi myocutaneous flap breast reconstruction; *European Journal of Surgical Oncology (EJSO)* Volume 24, Issue 3, June 1998, Pages 162-165
31. Tomita K, Yano K, Masuoka T, Matsuda K, Takada A, Hosokawa K: Postoperative seroma formation in breast reconstruction with latissimus dorsi flaps: a retrospective study of 174 consecutive cases. *Ann Plast Surg* 2007, 59:149-151.
32. Venus MR, Prinsloo DJ: Immediate breast reconstruction with latissimus dorsi flap and implant: audit of outcomes and patient satisfaction survey. *Journal of Plastic Reconstructive and Aesthetic Surgery* 2010, 63:101-105.

