

Patrick Harnarayan, Michael J. Ramdass, Ravi Maharaj,  
and Vijay Naraynsingh

---

### 3.1 Introduction

One of the most debilitating, painful, recurrent, malodorous, and costly conditions seen in the practice of surgery is the leg ulcers. These have always been a challenge for clinicians in terms of diagnosis and understanding of its pathophysiology. For instance, although the association between ulceration of the leg and varicose veins was observed more than 2000 years ago by Hippocrates [1], he thought that these ulcers were the site of release of the “evil humors” that plagued the body causing untold maladies. Thus, healing of the ulcers was frowned upon, and these ulcers were frequently reopened as described by Chadwick et al. [2]. Table 3.1 shows the various types of ulcers of the lower extremity. We herein look at the types of ulcers which are commonly seen in our surgical practice including the following: venous, arterial, mixed arterial, and venous; diabetic; neuropathic; hematological; lymphatic; Marjolin’s; malignant (primary and secondary); vasculitic; infective (necrotizing fasciitis, osteomyelitis, tuberculosis, and syphilitic); trauma; decubitus; calciphylaxis; hypertensive; and Bazin’s.

---

### 3.2 Venous Ulcer (Fig. 3.1)

Chronic venous insufficiency affects about 5 % of the adult population, and 1 % may have chronic leg ulcers in developed countries and a prevalence of 3–5 % in the population above 65 years of age [3, 4]. Ulcers of primarily venous origin can range between 54 and 57 % of chronic leg ulcers [5, 6]. Ulceration can begin before age

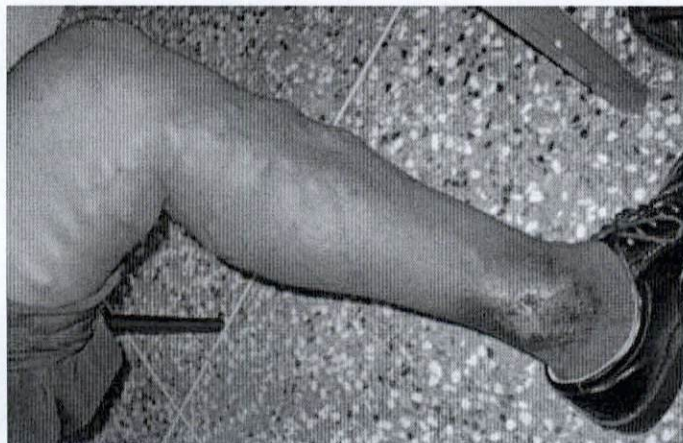
---

P. Harnarayan • M.J. Ramdass • R. Maharaj • V. Naraynsingh (✉)  
Department of Clinical Surgical Sciences, University of the West Indies,  
St. Augustine, Trinidad and Tobago, West Indies  
e-mail: vnarayn@gmail.com



**Table 3.1** Types of ulcer

Vascular	Venous
	Arterial
	Mixed
Neuropathic	Diabetes
	Tabes
	Syringomyelia
Metabolic	Diabetes
	Gout
	Prolidase deficiency
Hematological	Sickle-cell diseases
	Cryoglobulinemia
Trauma	Pressure
	Injury
	Burns
Tumors	Squamous cell carcinoma
	Marjolin's ulcer
	Basal cell carcinoma
	Melanoma
	Sarcomas
Infection	Bacterial
	Fungal
	Protozoal
Others	Hypertensive ulcer, Bazin's disease, pyoderma gangrenosum, fat necrosis, necrobiosis, calciphylaxis

**Fig. 3.1** Varicose ulcer due to saphenofemoral incompetence

3. of 40 [7], and many patients live with one throughout their entire adult life without seeing resolution. Venous disease utilizes 1–2 % of the health budgets of European countries with annual cost estimates being around £ 400 million in the United Kingdom and \$1 billion in the United States [1, 8].



Before 40, the gender incidence is equal, but above this the disease afflicts mainly the women [7] probably due to earlier pregnancies and hormonal factors [5, 6]. Venous disease has a multifactorial origin with prolonged standing, obesity, aging, pregnancy, and hereditary factors all playing a part [6].

Primary disease can be congenital when patients are born with valvular defects which herald themselves in the late teens or early twenties or familial when it affects generations and a familial factor does exist if one parent was involved and this is increased further if both parents had venous disease [5]. Secondary valvular problems range from trauma to the surrounding tissue, motor vehicular accidents with bony fractures and crush injuries, and post-thrombotic syndrome [5]. Deep vein thromboses (DVTs) associated with chronic leg edema, pigmentation, and ulceration were known as "postphlebotic syndrome" [9].

The pathology here is one of elevated venous pressure (venous hypertension) due to venous reflux through valves which are either primarily diseased or through pathological changes in the vein wall. In primary valve failure, there is degenerative change in the valve annulus and leaflets, while secondary failure is due to the diseased vein wall with secondary widening of the commissures leading to incompetence and reflux.

Venous disease is chronic, and venous ulcers tend to be more often recurrent when compared with the non-venous ulcers [10] and those with venous ulcers had a higher body mass index. Elevated venous pressure is the underlying cause of skin and soft tissue changes seen in chronic venous insufficiency (CVI) that ultimately lead to venous ulceration.

Increased venous pressure is transmitted to the venules and capillaries of the subcutaneous tissue causing a level with elongation of the capillary bed, increased type IV collagen in the basement membrane [9], and pericapillary fibrin cuff forms [11]. These capillaries which are not normal seem to have increased permeability to larger molecules. Protein such as fibrinogen and red cells then leak into the interstitium, and this fibrinogen converts to fibrin in the pericapillary space [11] and the fibrin is deposited together with hemosiderin [12], released during red cell destruction. Fibrinolytic activity appears deficient in patients with venous ulceration deposition so there is decreased fibrin clearance and reduced lymph drainage [13, 14]. In addition, fragmentation and obliteration of cutaneous lymphatics and decreased lymphatic flow correlate with the degree of venous hypertension [15–17]. Microscopically, capillaries also demonstrate microthrombi that are occlusive and white cells sludge [18]. Stagnation of blood flow and decreased oxygen levels occur, and the protein laden, edematous area then acts to decrease oxygen diffusion into the area leading to tissue hypoxia [19, 20]. There is good evidence that there is reduced cutaneous oxygenation [21]. This actually improves with oxygenation which indicates that a diffusion barrier exists and not an oxygen transport problem causing low oxygen tissue content which presumably plays a major part in genesis of the ulcer. This improves if oxygen is supplied to the area [19, 20].

Venous ulcers typically occur on the lower medial leg in the so-called gaiter area, but they can be seen nearly anywhere on the lower leg or dorsum of the foot [7]. They may be single or multiple, painful, and shallow with a red

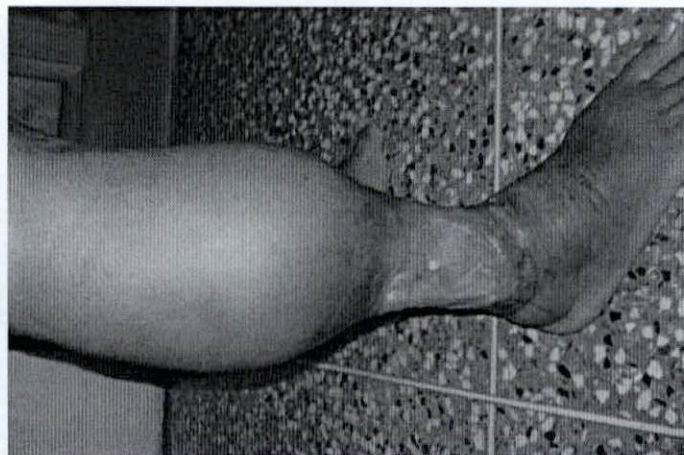


granulating floor, and usually there is a zone of stasis dermatitis and brown-to-black hemosiderin deposits [22] called lipodermatosclerosis. Edges may be clear-cut or irregular, and they extend onto the dorsum, up the leg, or become circumferential, and if present the ulcer will be found within this hyperpigmented area. Venous ulcers can be found on the lateral aspect of the dorsum as well especially when there is severe sapheno-popliteal reflux into the short saphenous venous system [23].

The skin becomes heavily pigmented and bound down to the subcutaneous tissue with extensive fibrosis which constricts the limb. This lipodermatosclerosis (LDS) usually occurs in the lower third of the leg with brawny edema above [9] the fibrosis and on the foot giving the typical appearance of an inverted champagne bottle with the neck being the area of lipodermatosclerosis and the edematous leg being the body of the bottle. Even though these areas of pigmentation are dark brown to black, there may be patches of depigmented macules called atrophie blanche, avascular and fibrotic in nature, that are thought to be forerunners to ulcer formation (Fig. 3.2) [9].

Clinically the changes include edema, dermatitis and eczema, hyper- or hypopigmentation (called atrophie blanche), and eventually tissue hypoxia leading to ulceration which is typically non-healing or recurrent [24].

Venous ulcers can be seen in patients with valvular incompetence at the superficial, deep, or perforating systems or a combination of two or even all three [25, 26], and in patients with ulcers, incompetence generally occurs at multiple locations [26]. Indeed some researchers studied closely the patterns of reflux and agree the incidence of multiple systems being involved in lower-limb venous ulcers was 64 % [27]. Furthermore, in 36 % patients with venous disease, one other etiological factor was a contributor to the chronic venous ulcer, and 96 % of these either had a previous history of a DVT or some condition that may have caused this pathology [28].

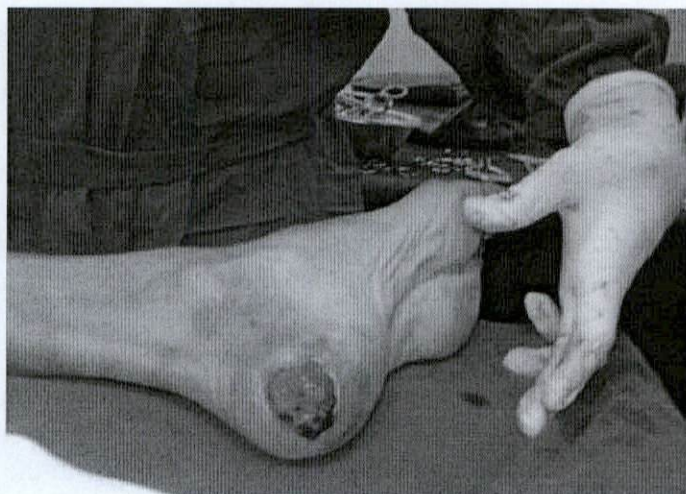

**Fig.3.2** Lipodermatosclerosis with ulceration

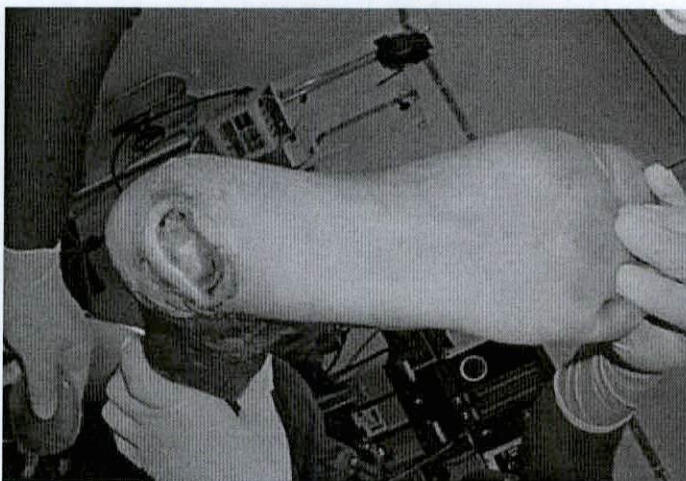


### 3.3 Arterial Ulcer (Figs. 3.3, 3.4, and 3.5)

Peripheral arterial disease is the only etiology identified in about 10 % of patients with leg ulcers [29]. Pure arterial ulceration is not as common as we may believe. One large study of 689 leg ulcers showed that only 15 limbs (2.2 %) were purely arterial in origin [2, 30] and another large study involving 1333 limbs with ulcers (1163 fully evaluated) indicated that 55 % were venous, 25 % were mixed, and 8.3 % were diabetic [3, 31], alluding to the fact that many clinicians do not separate leg ulcers into venous and arterial but venous, diabetic, and mixed origin. They believe that there is usually some other etiological factor present even if it is quiescent or subtle.



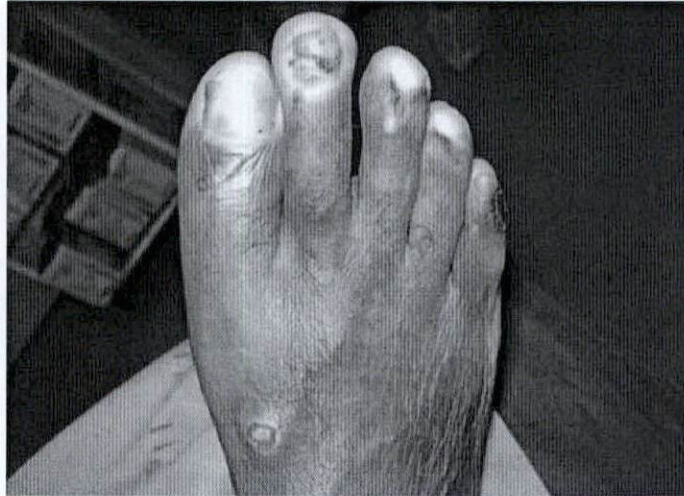**Fig. 3.3** Ischemic ulcer of the heel



**Fig. 3.4** Ischemic heel ulcer



**Fig. 3.5** Arterial ulcers on the dorsum and first three toes



Arterial ulcers of the leg tend to develop distally and are seen commonly on the toes and feet. They tend to be small and multiple and may occur in the areas commonly seen in venous disease or diabetes but are notorious for lying in unusual places such as the interdigital spaces, web-space areas, lateral dorsum, or plantar surface of the foot as well as the heel. They tend to be painful and they are usually dry and crusted and devoid of granulation tissue [5, 22].

Objective parameters to diagnose arterial insufficiency were considered to be ankle-brachial index (ABI)  $< 0.7$  and a toe systolic pressure (TP) of  $< 50$  mm Hg [4, 32]. Arterial disease is seen primarily in patients with atherosclerosis whether the cause is uncontrolled hypertension, chronic smoking, or diabetes, or in patients with dyslipidemias.

Most arterial leg ulcers may not be included in the category of chronic critical limb ischemia; however, they are unlikely to heal with conservative measures. An ankle pressure of 110 mmHg was able to determine those who should proceed to revascularization [1, 29], and generally they can be treated by conservative means using local therapy [4, 32], but wound care must be supplemented by active wound debridement, percutaneous transluminal angioplasty (PTA), or infrainguinal arterial bypass [6, 33].

The natural history of ischemic limb ulceration has not been well understood [4, 32]. Some patients with arterial ulcers can heal well in time without undergoing revascularization procedures such as angioplasty or arterial bypasses. Use of pressure relief, debridement, moist wound care, negative pressure, application of a strict antibiotic policy (with repeated wound swabs or tissue culture) for control of infections or special chemical debriding or granulation-producing agents, dipteran larvae (flies), or hyperbaric oxygen therapy (HBOT) may assist in wound healing [4, 32].

Limb salvage can be achieved in chronic non-healing ulcers that are uncomplicated, but if the ankle-brachial index (ABI) is less than 0.5, the end result can be a major amputation [4]. Infrainguinal bypasses are likely to result in wounds healing even if the ulcer was located in the heel area [6, 33], and limb salvage rates of  $> 85\%$  can be achieved once the graft remained patent but other factors are also relevant in



predicting healing. These included normal renal function, a palpable pedal pulse, a patent posterior tibial artery past the ankle joint, and the number of patent tibial arteries after completion of the bypass [6, 33]. Interestingly, the ABI, the presence of infection, diabetes, nor cardiovascular risks were unable to influence outcome of these ulcers [6, 33].

Therefore, most patients with an ulcer due to arterial insufficiency that is not complicated, even if appearing to be non-healing, may do so with local therapy. The patients with a low ABI and ankle and toe systolic pressure may attain limb salvage through percutaneous angioplasty or infrainguinal bypasses [29].

---

### 3.4 Mixed Arterial and Venous Ulcers

The mixture of venous and arterial disease is likely to be the second most common etiological factor leading to leg ulcers [31]. Combined arterial and venous insufficiency (CAVI) [34] accounted for the second largest group of patients with leg ulcers. In a study assessing 689 chronic leg ulcers, 14.5 % were of mixed origin as compared with those of a completely venous origin 72 % [30]. Elderly patients in this category may also have some degree of venous reflux giving rise to a "mixed" arteriovenous origin of the ulcers.

Clinically these patients can be difficult to diagnose due to the mixed symptoms and clinical signs with which they present. They may have some characteristics of arterial disease that may far overwhelm the venous picture such as a cold, dry dorsum of the foot, decreased pedal pulses, small ulcers on digits or dorsum of the foot, "hammer toes," with lipodermatosclerosis at the medial malleolar area leading an inexperienced clinician to think this may be a form of gangrene and ignore the venous component.

Alternately, a large medial malleolar ulcer typical of venous insufficiency may be accompanied by cutaneous gangrene of the covered toes or simply a dry withered foot with an absent dorsalis pedis pulse and loss of cutaneous hair on the lower leg but a good popliteal pulse. To the casual observer, this is venous disease, and the fact that the patient is diabetic or an ex-smoker of a pack a day prior to admission may be lost to an inexperienced medical officer.

Ulcers may develop anywhere on the foot or calf in mixed disease [34], and patients need the eye of an experienced clinician to properly assess and manage the patient. Patients with a previous history of a previous deep vein thrombosis (DVT) of the calf or thigh vessels complicate not only the diagnosis but subsequent treatment since these mixed ulcers are unlikely to heal [34].

In a large study of 689 limbs with chronic venous ulcers, 100 (14.5 %) were of mixed origin [30] and 56 had arterial revascularization via bypass procedures, 36 had venous surgery, 23 had local therapy (compression bandaging) whilst of 15 with pure arterial origin 13 had angioplasty (PTA) and the remaining 2 patients had dressings to the area [30]. This shows the multifactorial nature of the disease, the array of treatment options available, and therefore the treatment modalities adopted. Investigations always center on a careful clinical examination including bedside

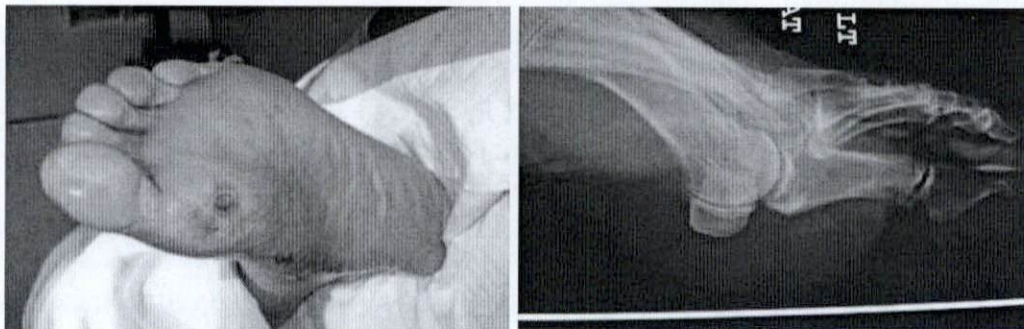


ankle-brachial index (ABI), handheld Doppler investigation, color flow duplex scan, and either MR, CT, or conventional arteriography. Ankle pressures are crucial in determination of the pathway management should follow and are required even with respect to the venous component since it allows estimation for the degree of compression allowed in the patient.

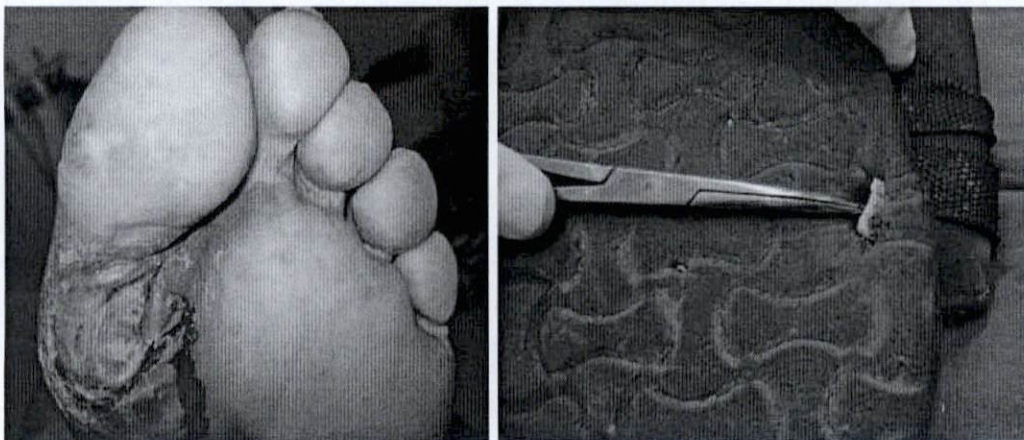
The value of ankle pressure of below 110 mmHg identified those patients for revascularization [29], but an ankle pressure (AP) of  $>$  or  $=$  80 mmHg predicts favorable outcome as well as a toe pressure of 30 mmHg [35]. In any case a practical bedside test such as the ankle-brachial index (ABI) of  $<$  0.5 should alert clinicians to seek revascularization for these slowly healing ulcers [29].

### 3.5 Diabetic/Neuropathic/Neuroischemic (Figs. 3.6, 3.7, 3.8, 3.9, and 3.10)

Diabetes mellitus patients may have a whole host of pathologies, some of which have the greatest effect on the foot. Ulceration of the foot is the commonest major end point in diabetic complications. Diabetic neuropathy and peripheral arterial



**Fig. 3.6** Neuropathic ulcer with underlying sesamoid bone



**Fig. 3.7** Traumatic neuropathic ulcer from foreign body embedded in slipper

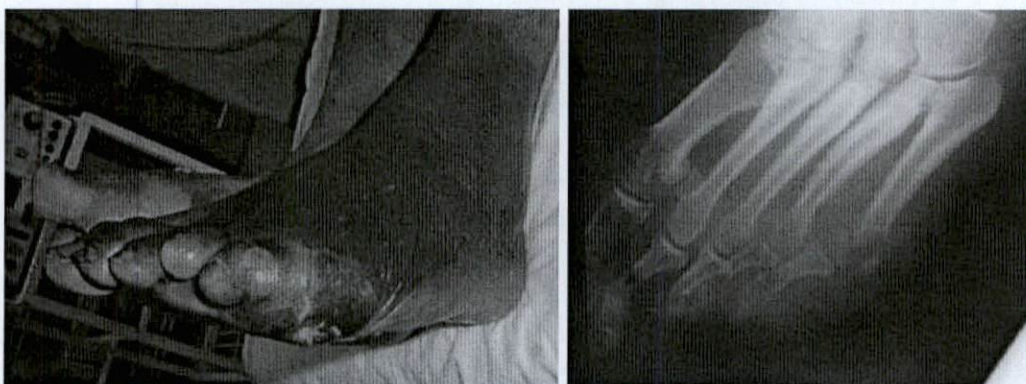

disease are the main players in foot ulceration alone or in tandem or with other factors such as mechanical issues (poor footwear, deformities with points of increased pressure), limited joint mobility, microvascular disease, and infections.

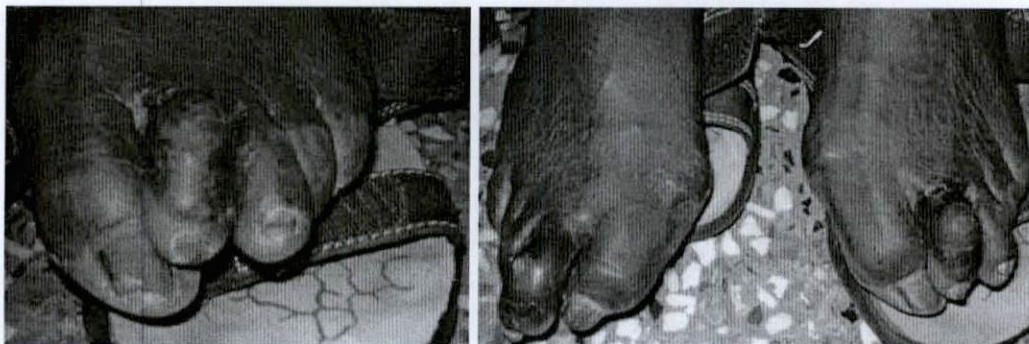
One study found foot ulceration in 7 % of diabetic patients over the age of 60 years; another study showed a 3 % history of ulceration in insulin-dependent diabetes patients (IDDM); patients aged 15–50 years are 45–60 % purely neuropathic, 10 % are purely ischemic, and 25–45 % are mixed.

Neuropathic ulcers are usually at the site of repeated trauma as in the area at the metatarsal heads where a high pressure exists or dorsal surface of the “hammer toes” or the distal-most portion of these hammer toes where there is flexion at the interphalangeal joint (IPJ) of these “clawed” toes. The foot is warm, well perfused, and pulse bounding. A foreign body may get lodged in the footwear, or a sharp object like a nail can penetrate the shoe or slipper. The presence of callus continues to impede ulcer healing since wounds heal from margins or edge, and epidermal cells from this area are prevented from so doing by position of the callus.

The pure ischemic ulcer is rare and most are neuroischemic occurring at the medial aspect of the first metatarsal head, the heel, and the digits. There is no callus present but there is a ring of hyperemia, with or without a necrotic center. Again ulcer formation is preceded by mild trauma and the tight or poorly fitting usually “under”-sized shoe in women and the hard boot in the industrial areas. Diabetic



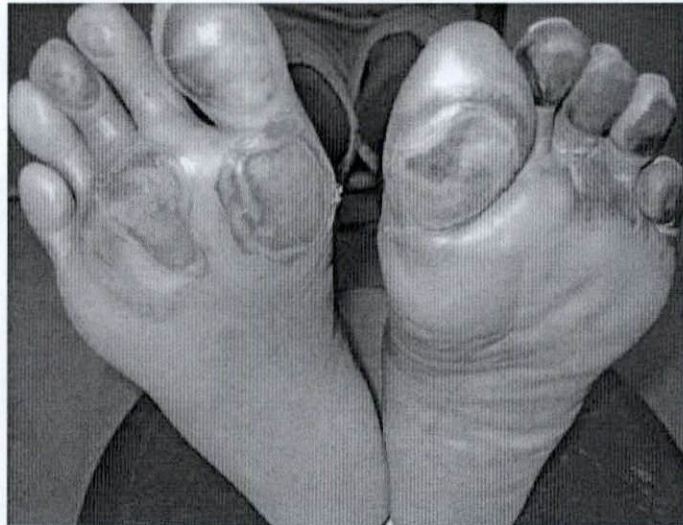**Fig. 3.8** Neuropathic ulcer opposite to the 5th metatarsal head with underlying bony destruction



**Fig. 3.9** Ulcers on the dorsum of hammer toes



**Fig. 3.10** Ulcers from neuropathic foot on hot surface



neuropathy affects approximately 30–50 % of patients. Diabetics then suffer from another source of ulceration, namely, those of a neuropathic origin which tends to be typically small, shallow, and painful and lies in relation to the digits and the plantar surface of the hallux at the metatarsal-phalangeal joint (MPJ). The ulcers in diabetics could be ischemic, neuropathic, or mixed neuroischemic. These account for the majority of ulcers seen in the practice of clinical surgery at the emergency room, clinic, or long-stay “sepsis ward.” However, they are not by any means the only (etiology of) ulcers encountered in practice of surgery, and indeed there are more striking, chronic, and lethal forms of ulcers encountered on the legs and feet of patients.

### 3.6 Hematological Ulcers

Patients with hematological diseases such as sickle-cell anemia as well as  $\beta$ -thalassemia (genetic disorders of hemoglobin synthesis frequently present with leg ulcers, which tend to be painful and slow to heal [1–3, 36–38]. The incidence varies from 8 to 10 % of sickle-cell patients (with the homozygote SS disease) between ages of 10 to 50 years [36]. Leg ulcers did not occur in sickle beta plus thalassemia and sickle hemoglobin C disease. Low steady-state hemoglobin patients had a higher incidence of ulcer formation, and fetal hemoglobin seemed to have a protective effect on sickle-cell patients [36]. The pathophysiology of the ulcers is unclear, but there may be a relation to vaso-occlusive complications where decreased oxygen-carrying capacity of the abnormal hemoglobin has been suggested [39]. There were no ulcers in patients below age 10, and males were much more affected than female patients for reasons unknown to clinicians [36].

Even though the exact etiology remains unknown, another theory advanced is one related to the hemorheological changes (blood cell deformability, blood viscosity, and aggregation properties), and the hemolytic pathways leading to anemia may be responsible. The hematocrit-to-viscosity ratio (HCT/viscosity or HVR) appears



to give an idea of the blood oxygen transport system and is lower in the patients with leg ulcers [40].

This really indicates a lower hemoglobin level and a higher viscosity (and therefore probable hypercoagulability) and when taken together with decreased red cell deformability it probably explains why this group of sickle-cell patients had a higher prevalence of leg ulcers even though the viscosity and deformability characteristics seem to oppose each other [41]. Other malignant hematological disorders such as lymphomas and leukemias can present with leg ulcers [42]. Not only are traditional T-cell lymphoma skin lesions associated with multiple extremity ulcers [43] but patients with B-cell lymphomas (including post-transplant lymphoproliferative disorders as well as Epstein-Barr virus driven large B-cell lymphomas) can manifest themselves as well, since primary cutaneous B-cell lymphomas (PCBCL) are the second most common cause of primary cutaneous lymphomas [44].

---

### **3.7 Rheumatoid Arthritis Ulcers**

Rheumatoid arthritis (RA) patients can present with extra-articular findings such as ulcerated rheumatic nodules, ischemic vasculitic lesions, pyoderma gangrenosum [1, 45], and gangrene [2, 46]. These are characteristic of the disease; however, rheumatoid arthritis patients have a more complex picture since chronic venous disease, peripheral arterial disease, and combined arteriovenous etiologies coexist [45]. Rheumatoid arthritis patients tend to develop gravitational leg ulcers and pressure ulcers on their legs and around their ankles that can be visualized as punched-out indolent ulcers that are slow to heal and can be quite painful [3, 47]. Due to the existence of dermal infarction, a necrotizing arteritis would be more likely the cause of these ulcers than the expected vasculitis [46].

---

### **3.8 Vasculitis-Associated Ulcers**

Cutaneous vasculitis is an uncommon cause of ulceration in the lower limb [1]; sometimes these patients present with mild skin lesions like purpura, erythema, or severe infarction of the skin with ulceration. There may be an increased incidence of hypercoagulability with patients presenting with vasculitic ulcers [2] which may explain the larger-than-expected size. In Sjogren's syndrome characterized by dryness of the mucous membranes, xerostomia and xerophthalmia are present, but this uncommon chronic autoimmune disease may have leg ulcers that are painful and difficult to treat. Polyarteritis nodosa can occur with hematologic malignancies, characterized by palpable purpura, while small-vessel vasculitis causing leg ulcers can be drug induced as seen in some patients taking hydroxyurea therapy (for myeloproliferative disorders) [3]. They are painful ulcers occurring on the dorsum of the foot or lateral malleolar area that may disappear on cessation of hydroxyurea therapy.



### 3.9 Connective Tissue Disease: Ehlers-Danlos with Ulceration

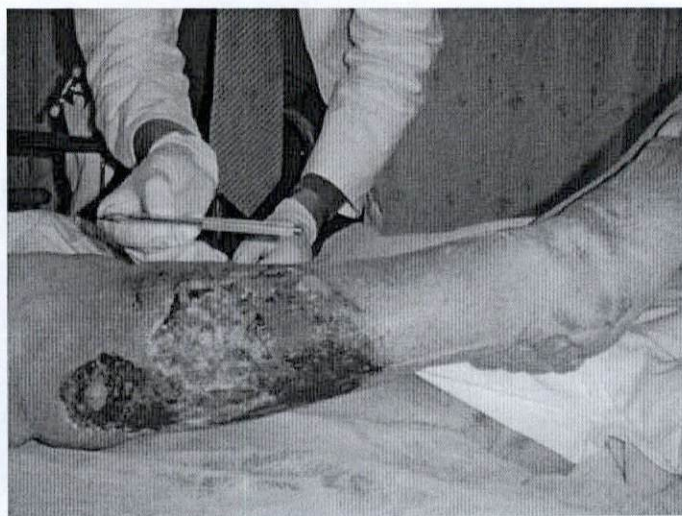Connective tissue disorders such as Ehlers-Danlos syndrome (type VIII) are very rare autosomal dominant diseases usually characterized with periodontic disease at a young age. Skin fragility, atrophic scars, and relatively thin skin are seen together with atrophic pretibial plaques and leg ulcers which is pyoderma gangrenosum, a rare inflammatory noninfective, nonneoplastic skin disorder with association to systemic disease like rheumatoid arteritis, inflammatory bowel disease, or hematologic malignancy [1]. There are enlarging necrotic ulcers with advancing zones of erythema.

### 3.10 Traumatic (Figs. 3.11, 3.12, 3.13, and 3.14)

Traumatic ulcers may arise in a number of scenarios and may be considered a complex wound. Such a wound is defined as a difficult wound or ulcer that challenges the skill of doctors and nurses. They usually are difficult to heal and may require more complex dressings such as vacuum-assisted closure and have a significant psychosocial impact on the patient and a major economic impact on healthcare systems. They usually require skin grafting and complex flaps and the help of a multidisciplinary team approach to achieve closure [48].

When we think of trauma, we think of road traffic accidents, penetrating injury related to violence such as gunshots and stabs, and work-related crush-type injury, impalement, and burns. These can all result in a non-healing chronic ulcer affecting the upper limb, lower limb, or elsewhere on the body.

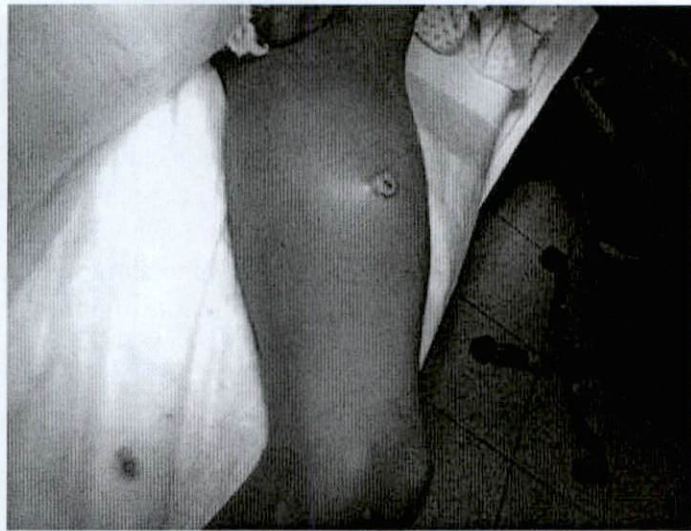We must be mindful that there is an iatrogenic component whereby ulceration may result after surgery to a limb and may be worse in cases such as



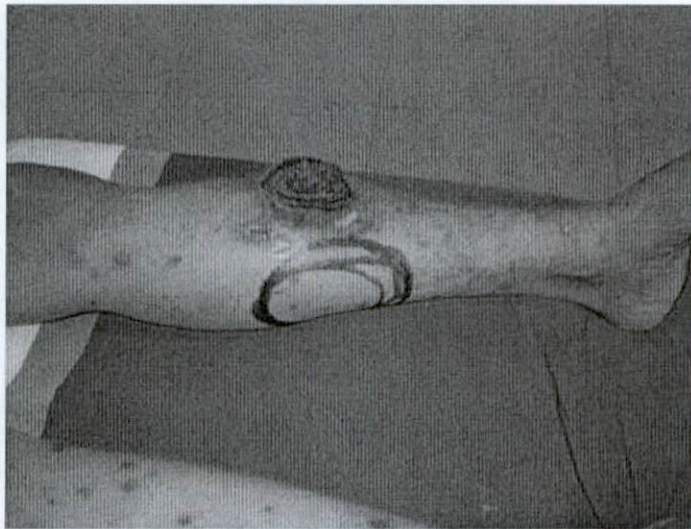
**Fig. 3.11** Chronic ulceration from previous trauma to the lower limb



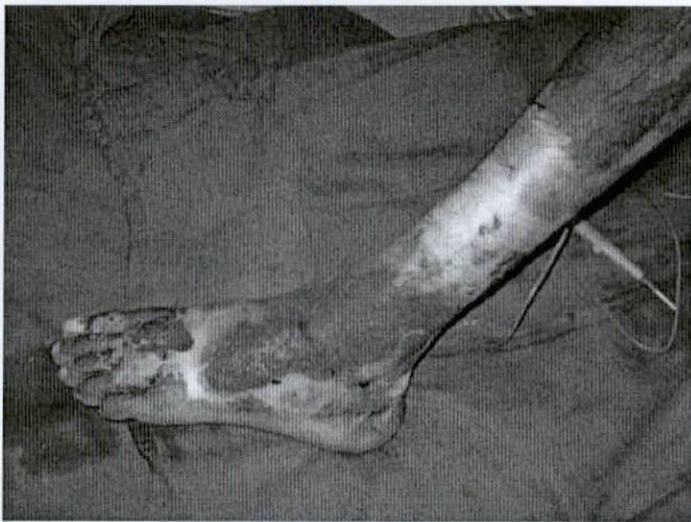
**Fig. 3.12** Gunshot wound to the left thigh with false aneurysm formation and ulceration of entry wound with impending rupture



**Fig. 3.13** Traumatic ulcer – not healing for 6 months



**Fig. 3.14** Chemical burn ulcer





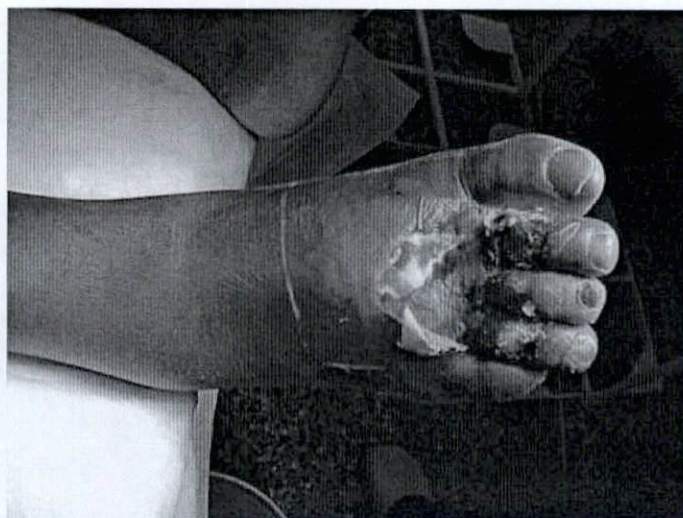a degloving injury with a compound fracture as per Gustilo-Anderson classification [49]. After debridement and surgical reconstruction, many patients return years later with chronic ulceration of the lower limb which is difficult and slow to heal.

Clinically, the presentation is that of a chronic, non-healing ulcer usually around the distal leg area, ankle, anterior tibial region, gaiter area, or foot. They are usually deep and very painful. Therefore, it is essential to investigate and exclude vascular compromise in these cases and intervene along the lines of angioplasty or bypass surgery when required and surgical reconstruction using pedicled or free flaps as required [50]. Infection may be associated with slow healing, and one must always be mindful of MRSA, pseudomonas, and other atypical and hospital-acquired infections that are difficult to treat but contribute significantly to the pathological process.

### 3.11 Infective Ulcers

Infections may cause ulcers on the lower limb in a number of situations. The most common scenario is due to an infection in after trauma, a burn, the diabetic foot [51], or necrotizing fasciitis [52]. More rare situations occur in elephantiasis [53], lymphedema [54], and pathogenic bacteria as in tuberculosis [55], syphilis [56], and leprosy [57]. Syphilitic ulcers may occur elsewhere such as the mouth, tongue, and penis. Chronic osteomyelitis after a compound fracture may also lead to chronic painful non-healing ulcers and chronic discharging sinuses (Figs. 3.15, 3.16, 3.17, 3.18, 3.19, 3.20, 3.21, and 3.22) [58].

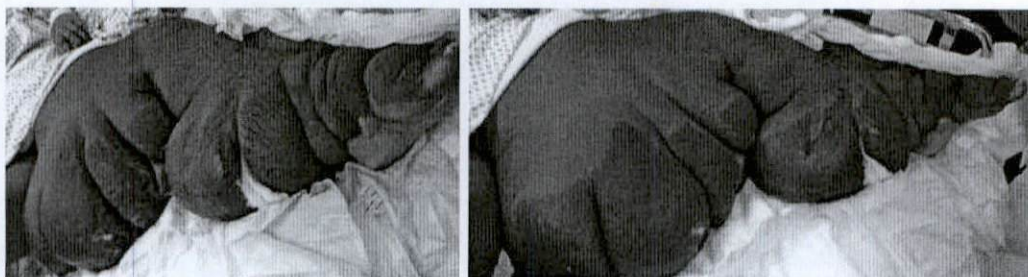
Chronic ulcers despite etiology may become infected with bacterial organisms. In a study conducted by Tascini et al. on 1295 patients, Gram-positive organisms were the most common isolate accounting for 52.6 % of cases. *Staphylococcus aureus* was the most common organism accounting for 29.9 % (MRSA was 22 % of *Staphylococcus aureus*) followed by *Enterococcus faecalis* (9.9 %), streptococci



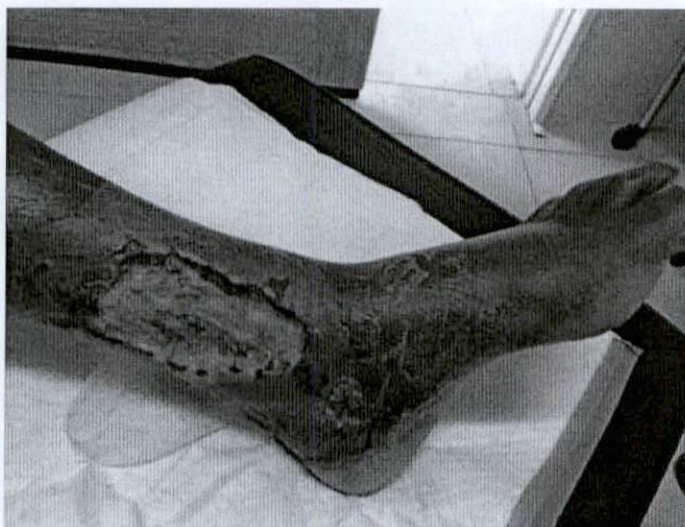**Fig. 3.15** Infected diabetic foot



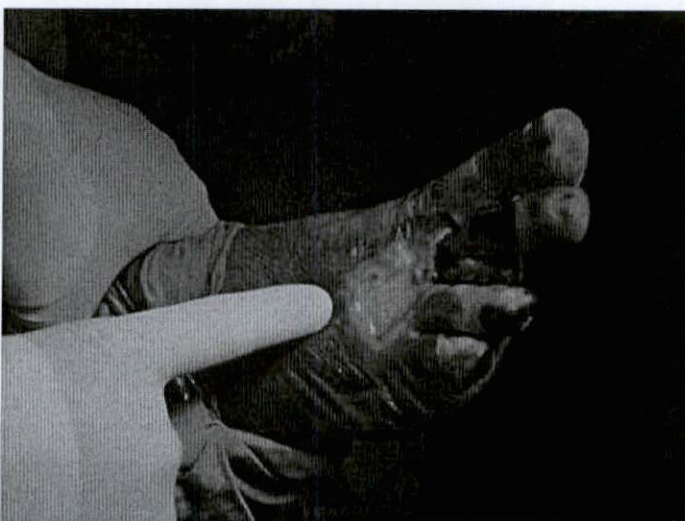
(4.6%), and *Pseudomonas aeruginosa* (10.3%). Anaerobes were less than 1%, and extended-spectrum beta-lactamase producers were *Escherichia coli* and *Proteus* species [52].



**Fig. 3.16** Elephantiasis and lymphedema with superimposed skin necrosis and infection



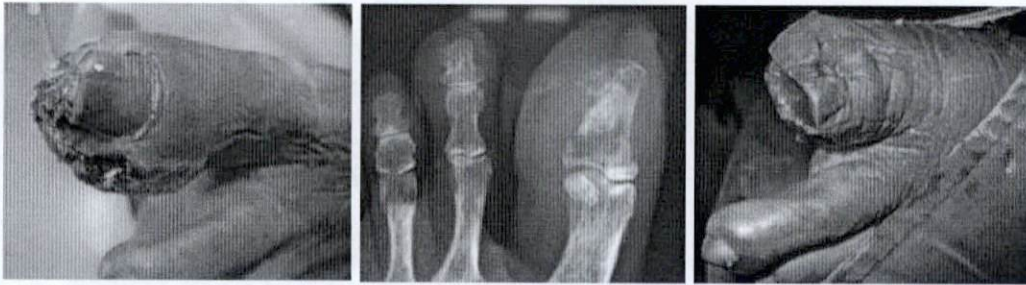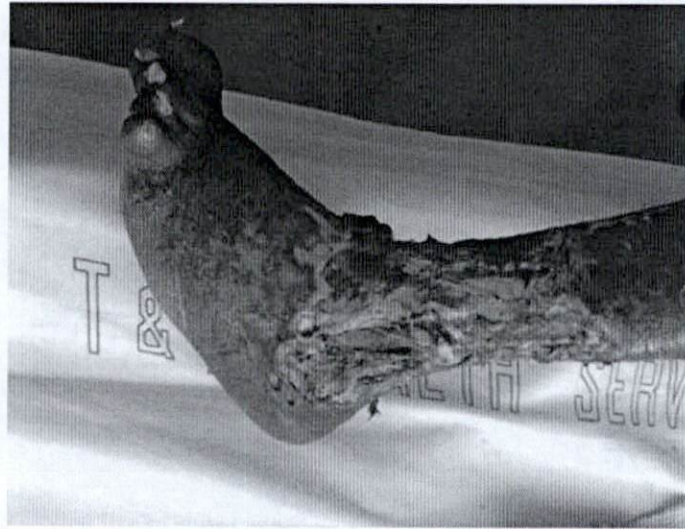
**Fig. 3.17** Infected ulcer  
venous ulcer in the gaiter  
area



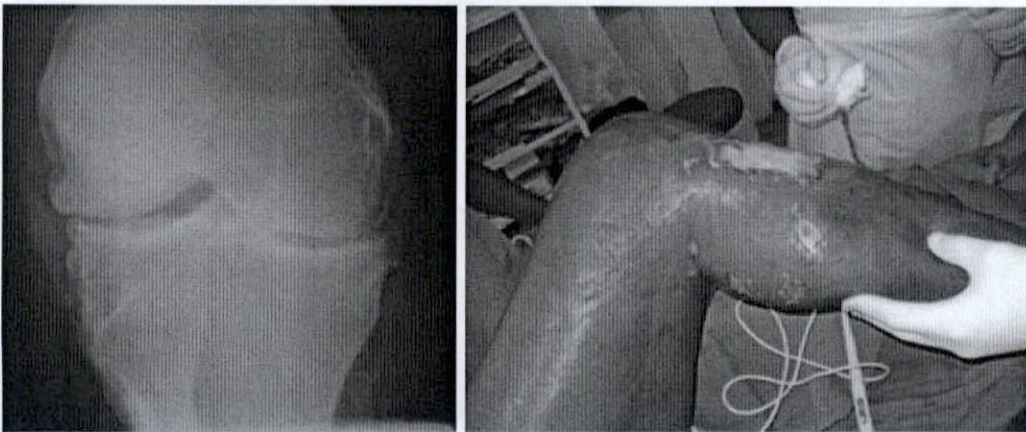
**Fig. 3.18** Ischemic ulcers  
affecting the dorsum of the  
foot and digits with MRSA  
infection



**Fig. 3.19** Chronic mixed venous and arterial ulceration with superimposed infection with coliforms



**Fig. 3.20** Osteomyelitis with non-healing hallux ulceration. Though appearing ischemic, the blood supply is good



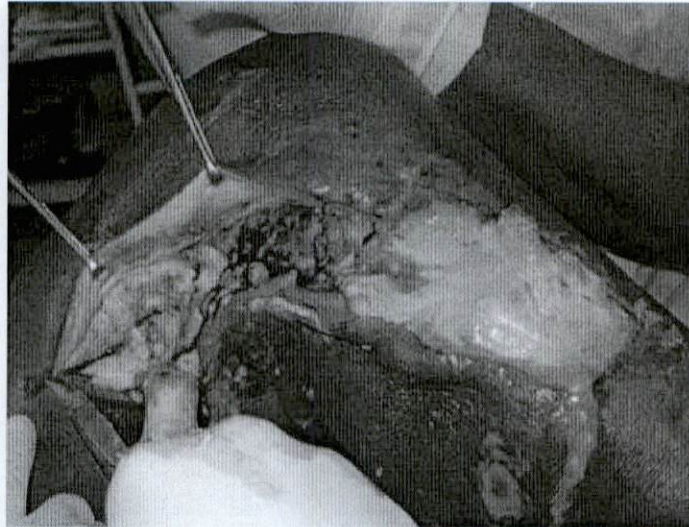**Fig. 3.21** Gas in subcutaneous tissue and necrotizing fasciitis

### 3.12 Malignancy

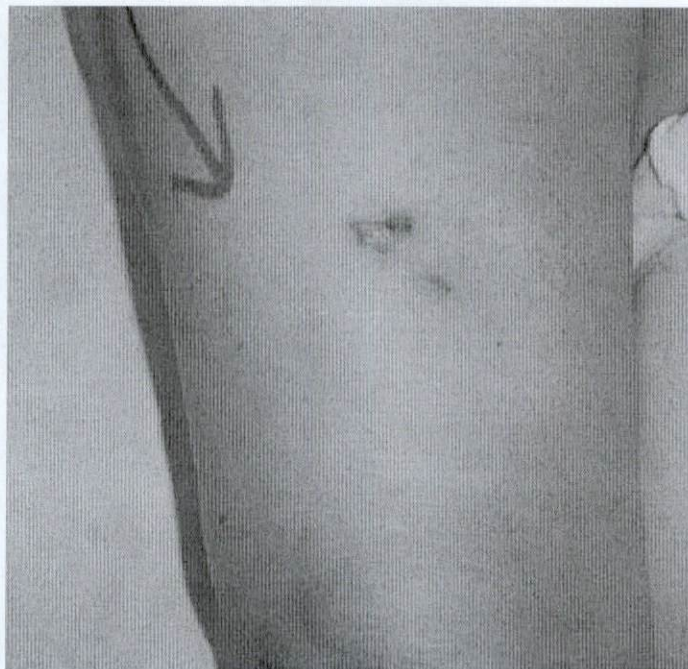
Malignant ulcers can be classified as primary and secondary. Primary malignant ulcers include those arising from the skin including basal cell carcinoma, squamous cell carcinoma (Fig. 3.23), and malignant melanoma. A study done by



**Fig. 3.22** Subcutaneous pus and fascial gangrene



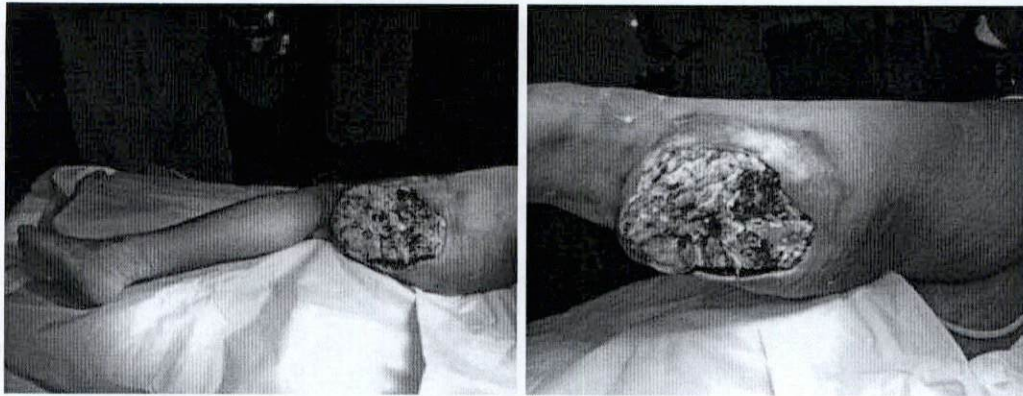**Fig. 3.23** Squamous cell carcinoma on the thigh with ulceration



*Pilgrim et al.* in 2014 details the epidemiology of skin malignancy and found basal cell carcinoma to be the most common and accounting for the majority of healthcare costs [59].

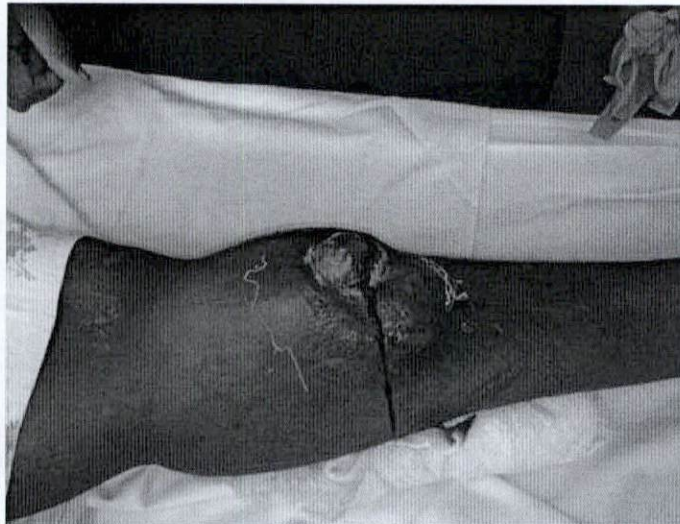Ulcerating tumors may include liposarcomas and sarcomas from other tissues such as leiomyosarcomas of smooth muscle origin, rhabdomyosarcomas [60] of skeletal muscle origin, and advanced malignant bone tumors as may occur in the developing world setting (Figs. 3.24 and 3.25). These include osteosarcoma, chondrosarcoma, and chondrofibrosarcoma. A Marjolin's ulcer of a chronic venous ulcer may be considered a secondary malignancy.





**Fig. 3.24** Advanced rhabdomyosarcoma of the thigh with ulceration after radiation. The patient went on to have a hindquarter amputation

**Fig. 3.25**  
Rhabdomyosarcoma of the proximal anterior compartment of the leg



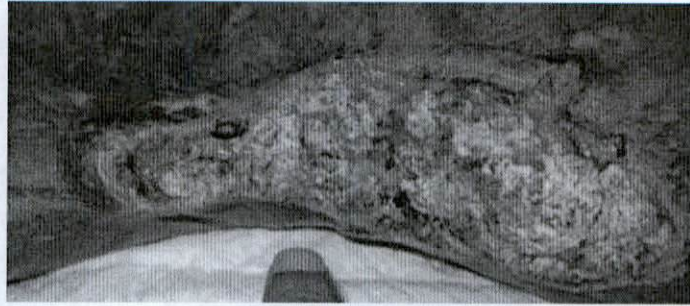### 3.13 Marjolin's Ulcer

Marjolin's ulcers are malignancies that arise in chronic venous ulcers, scars, burns, long-standing wounds, or sinuses [1]. A Marjolin's ulcer is a carcinoma that develops in chronic benign ulcers or scars (Fig. 3.26). The concept of or the term "Marjolin's ulcer" is generally representative of/refers to a long-term malignant complication of the scars resulting from burn. It was first described by the French Surgeon Jean-Nicolas Marjolin in 1828. It was originally associated with chronic osteomyelitis [2] but is seen in many different types of chronic wounds or in an area of chronically inflamed or scarred skin; it can occur in the quiescent scar overlying osteomyelitis [3].

Clinically they occur in middle-aged to older men, three times more commonly than women [4]. Any part of the body can be affected, but the extremities and scalp are the areas most commonly involved [5]. Usually involving the lower limb, they most often occur in the tibial region with typically increased bone destruction on



**Fig. 3.26** Marjolin's ulcer in burn scar



radiographs. Earlier believed to be benign, these ulcers are sometimes called the skin malignancy of developing countries where a non-healing ulcer undergoes a malignant change over a period of a few decades and the patient only seeks advice of a physician for symptoms of increased pain, discharge with foul odor, and bleeding. The patient usually presenting with increased pain in a chronic fungating ulcer which has an unusually foul-smelling drainage, and occasional heavy bleeding for which they usually seek medical advice. A change in the size of the ulcer as evidenced by a fungating or exophytic growth or in its nature, such as “heaped-up” edges, is suspicious as well as persistent bleeding, recent or enlarging inguinal lymphadenopathy [6] or an abnormal radiograph showing severe underlying bone destruction.

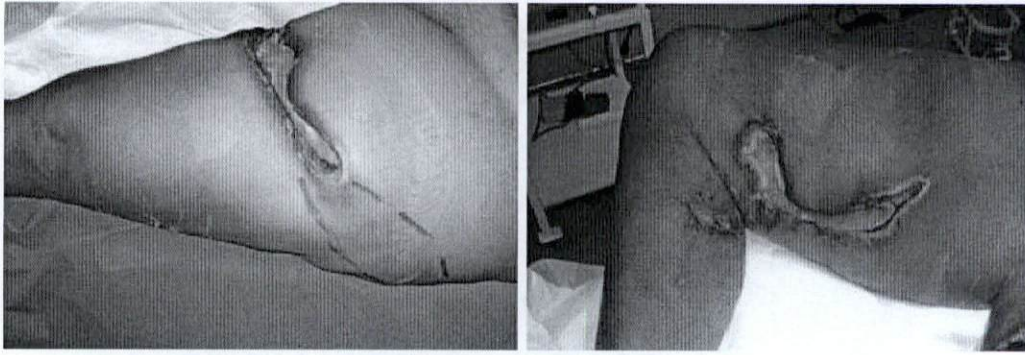
### 3.14 Calciphylaxis

Calciphylaxis is a syndrome of disseminated calcification (uremic gangrene syndrome) and is a rare and life-threatening condition occurring in 1 % of patients with chronic renal failure (CRF)/end-stage renal disease (ESRD) on dialysis each year with secondary hyperparathyroidism characterized by medial calcinosis of dermal arteriolar vessels leading to skin necrosis, ischemia, and then secondary infection. These hemodialysis patients suffer from various metabolic derangements and ectopic deposition of calcium in the skin, soft tissue, and vessel walls lead to abnormal condition of calcium and phosphate homeostasis (Fig. 3.27) [61].

The calcification of microvascular system and thrombosis and microvascular occlusion cause painful, violaceous lesions of the trunk and extremities. The lower extremities are predominantly involved in 90 % of patients that progress to subcutaneous tissue necrosis, non-healing ulcers, and gangrene skin lesions which become necrotic and can lead to non-healing ulcers. Secondary infection occurs with systemic sepsis and demise. The path physiology is not well understood, and although these patients have abnormal calcium-phosphate axis or elevated parathyroid hormone levels, these are not crucial to the eventual outcome.

Recently a functional protein C deficiency has been postulated to cause the hypercoagulable state which produces small-vessel thrombosis, skin ischemic necrosis, and then gangrene. By extension warfarin, a vitamin K antagonist, has been implicated in calciphylaxis. Rare cases not associated with ESRD include breast





**Fig. 3.27** Ulcers associated with calciphylaxis

carcinoma, hyperparathyroidism, alcoholic cardiomyopathy, and alcoholic cirrhosis. Indeed though calciphylaxis is characterized by spontaneous skin ulcers that progress to deep tissue necrosis, it can present in ESRD prior to dialysis and must be considered in a differential even if patient is not yet dialyzing. The lower extremity is the commonest location (90 %), and the trunk has been recorded in cardiac and alcoholic cardiomyopathy. The diagnosis lies in serologic and histopathologic findings and can only be healed by immunosuppressive therapy with modern wound therapy polyarteritis nodosa occurring with hematologic malignancies [62].

---

### 3.15 Bazin's Ulcer

Named after the French physician Pierre-Antoine-Ernest Bazin, the Bazin's ulcer, also known as erythema induratum or nodular vasculitis, is essentially panniculitis typically involving the calf region of adolescent and middle-aged females (Fig. 3.28). Usually occurring in the lower third of the posterior calf but can also involve the thigh and gluteal region, these ulcers commence as multiple painful nodules, sometimes red in color. The nodules eventually ulcerate leading to bluish irregular borders. Bazin's ulcers were initially thought to be directly related to tuberculous infection; however, the etiology is now multifactorial with the term Bazin's ulcer used when tuberculosis is the causative agent and Whitfield type for nontuberculosis etiology [63–65].

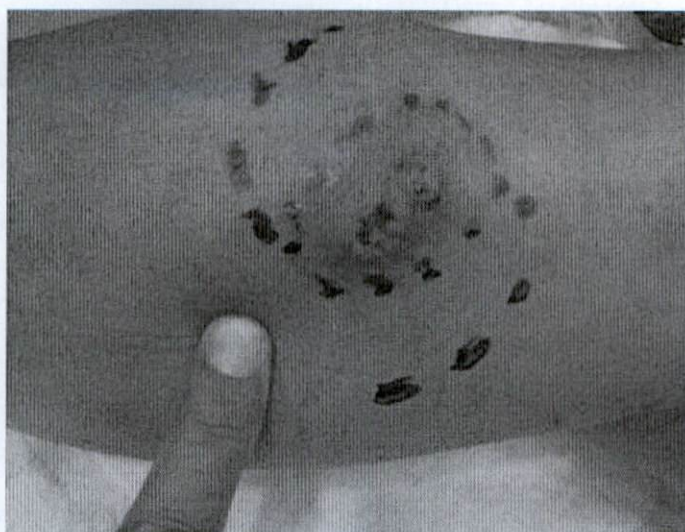---

### 3.16 Martorell's Ulcer

First described by the Spanish cardiologist Fernando Martorell and also known as hypertensive ulcers, these are quite uncommon and associated with severe, uncontrolled diastolic hypertension. The ulcers commonly are located on the anterolateral aspect of the supramalleolar region as opposed to the typical gaiter region of venous ulcers. Less commonly, the region over the Achilles tendon can be affected. Despite the small inconspicuous size, they are characteristically exquisitely



**Fig. 3.28** Bazin's ulcer – nodular vasculitis



tender. Despite the pain, the easily palpable pulses differentiate the Martorell's ulcer from the more common arterial ulcer. The ulcer tends to be quite deep with tendon exposure and erythematous and irregular edges with a symmetrical distribution. Histology revealed arteriole hyalinization. Treatment is based on rigid hypertensive control with some success with oral anticoagulation and lumbar sympathectomy [66, 67].

### Conclusion

There may be a variety of ulcerations in the lower extremity, but the common ones are venous, arterial, and diabetic ulcers. Other types of ulcer form a very small percentage. There should be a good approach to investigate these patients to make a proper diagnosis so that an appropriate treatment may be started. These ulcers may be very chronic and require a very good psychosocial support apart from the treatment of the ulcers.

### References

1. Van Gent WB, Hop WC, van Praag MC, Mackaay AJ, de Boer EM, Wittens CH. Conservative versus surgical treatment of venous leg ulcers: a prospective, randomized, multicenter trial. *J Vasc Surg.* 2006;44(3):563–71.
2. Chadwick J, Mann WN. *The medical works of Hippocrates.* Oxford: Blackwell; 1950.
3. Ruckley CV. Socioeconomic impact of chronic venous insufficiency and leg ulcers. *Angiology.* 1997;48(1):67–696.
4. Mekkes JR1, Loots MA, Van Der Wal AC, Bos JD. Causes, investigation and treatment of leg ulceration. *Br J Dermatol.* 2003;148(3):388–401.
5. Carpentier P1, Priollet P. Epidemiology of chronic venous insufficiency. *Presse Med.* 1994;23(5):197–201.
6. Carpentier PH. Epidemiology and physiopathology of chronic venous leg diseases. *Rev Prat.* 2000;50(11):1176–81.
7. Callam MJ, Harper DR, Dale JJ, Ruckley CV. Chronic ulcer of the leg: clinical history. *Br Med J (Clin Res Ed).* 1987;294(6584):1389–91.



8. Whiddon Lonnie L. The treatment of venous ulcers of the lower extremities. *Proc (Bayl Univ Med Cent)*. 2007;20(4):363–6.
9. Alguire P, Mathes BM. Chronic venous insufficiency and venous ulceration. *J Gen Intern Med*. 1997;12:374–83.
10. Nelzen O, Bergqvist D, Lindhagen A. Leg ulcer etiology – a cross sectional population study. *J Vasc Surg*. 1991;14(4):557–64.
11. Burnand KG, Whimster I, Naidoo A, Browse NL. Pericapillary fibrin in the ulcer-bearing skin of the leg: the cause of lipodermatosclerosis and venous ulceration. *BMJ*. 1982;285:1071–2.
12. Leach RD, Browse NL. Effect of venous hypertension on canine hind limb lymph. *Br J Surg*. 1985;72:275–8.
13. Browse NL, Gray L, Jarrett PEM, Morland M. Blood and vein-wall fibrinolytic activity in health and vascular disease. *BMJ*. 1977;1:478–81.
14. Wolfe JHN, Morland M, Browse NL. The fibrinolytic activity of varicose veins. *Br J Surg*. 1979;66:185–7.
15. Bollinger A, Isenring G, Franzeck UK. Lymphatic microangiopathy; a complication of severe chronic venous insufficiency. *Lymphology*. 1982;15:60–5.
16. Bollinger A, Pfister G, Hoffman U, et al. Fluorescence microlymphology in chronic venous incompetence. *Int Angiol*. 1989;8:23–6.
17. Bull RH, Gane JN, Evans JEC, Joseph AEA, Mortimer PS. Abnormal lymph drainage in patients with chronic venous leg ulcers. *J Am Acad Dermatol*. 1993;28:585–90.
18. Leu HJ. Morphology of chronic venous insufficiency – light and electron microscopic examinations. *Vasa*. 1991;20(4):330–42.
19. Partsch H. Hyperaemic hypoxia in venous ulceration. *Br J Dermatol*. 1983;109:249–50.
20. Partsch H. Investigations on the pathogenesis of venous leg ulcers. *Acta Chir Scand Suppl*. 1988;544:25–9.
21. Mani R, White JE, Barrett DF, Weaver PW. Tissue oxygenation, venous ulcers and fibrin cuffs. *J R Soc Med*. 1989;82(6):345–6.
22. Tam M, Moschella SL. Vascular skin ulcers of limbs. *Cardiol Clin*. 1991;9(3):555–63.
23. Bass A1, Chayen D, Weinmann EE, Ziss M. Lateral venous ulcer and short saphenous vein insufficiency. *J Vasc Surg*. 1997;25(4):654–7.
24. Valencia IC, Falabella A, Kirsner RS, Eaglstein WH. Chronic venous insufficiency and venous leg ulceration. *J Am Acad Dermatol*. 2001;44(3):401–21.
25. Shami SK, Sarin S, Cheattle TR, Scurr JH, Smith C. Venous ulcers and the superficial venous system. *J Vasc Surg*. 1993;17(3):487–90.
26. Hanrahan LM, Araki CT, Rodriguez AA, Kechejian GJ, LaMorte WW, Menzoian JO. Distribution of valvular incompetence in patients with venous stasis ulceration. *J Vasc Surg*. 1991;13(6):805–11.
27. Labropoulos N, Leon M, Geroulakos G, Volteas N, Chan P, Nicolaides AN. Venous hemodynamic abnormalities in patients with leg ulceration. *Am J Surg*. 1995;169:572–4.
28. Baker SR, Stacey MC, Jopp-McKay AG, Hoskin SE, Thompson PJ. Epidemiology of chronic venous ulcers. *Br J Surg*. 1991;78(7):864–7.
29. Hafner JI, Schaad I, Schneider E, Seifert B, Burg G, Cassina PC. Leg ulcers in peripheral arterial disease (arterial leg ulcers): impaired wound healing above the threshold of chronic critical limb ischemia. *J Am Acad Dermatol*. 2000;43(6):1001–8.
30. Adam DJI, Naik J, Hartshorne T, Bello M, London NJ. The diagnosis and management of 689 chronic leg ulcers in a single-visit assessment clinic. *Eur J Vasc Endovasc Surg*. 2003;25(5):462–8.
31. Apollonio A, Antignani PL, Di Salvo M, Failla G, Guarnera G, Mosti G, Ricci E; SUV Study Group. A large Italian observational multicentre study on vascular ulcers of the lower limbs (Studio Ulcere Vascolari). *Int Wound J*. 2014. doi: 10.1111/iwj.12216.
32. Marston WA1, Davies SW, Armstrong B, Farber MA, Mendes RC, Fulton JJ, Keagy BA. Natural history of limbs with arterial insufficiency and chronic ulceration treated without revascularization. *J Vasc Surg*. 2006;44(1):108–14.



33. Treiman GS1, Oderich GS, Ashrafi A, Schneider PA. Management of ischemic heel ulceration and gangrene: an evaluation of factors associated with successful healing. *J Vasc Surg.* 2000;31(6):1110–8.
34. Treiman GS1, Copland S, McNamara RM, Yellin AE, Schneider PA, Treiman RL. Factors influencing ulcer healing in patients with combined arterial and venous insufficiency. *J Vasc Surg.* 2001;33(6):1158–64.
35. Wütschert R1, Bounameaux H. Predicting healing of arterial leg ulcers by means of segmental systolic pressure measurements. *Vasa.* 1998;27(4):224–8.
36. Koshy M1, Entsuaah R, Koranda A, Kraus AP, Johnson R, Bellvue R, Flournoy-Gill Z, Levy P. Leg ulcers in patients with sickle cell disease. *Blood.* 1989;74(4):1403–8.
37. Matta BN1, Abbas O, Maakaron JE, Koussa S, Daderian RH, Taher AT. Leg ulcers in patients with  $\beta$ -thalassaemia intermedia: a single centre's experience. *J Eur Acad Dermatol Venereol.* 2014;28(9):1245–50. doi:10.1111/jdv.12211.
38. Ladizinski B1, Bazakas A, Mistry N, Alavi A, Sibbald RG, Salcido R. Sickle cell disease and leg ulcers. *Adv Skin Wound Care.* 2012;25(9):420–8.
39. Chung C1, Cackovic M, Kerstein MD. Leg ulcers in patients with sickle cell disease. *Adv Wound Care.* 1996;9(5):46–50.
40. Connes P, Lamarre Y, Hardy-Dessources MD, Lemonne N, Waltz X, Mougengel D, Mukisi-Mukaza M, Lalanne-Mistrih ML, Tarer V, Tressières B, Etienne-Julan M, Romana M. Decreased hematocrit-to-viscosity ratio and increased lactate dehydrogenase level in patients with sickle cell anemia and recurrent leg ulcers. *PLoS One.* 2013;8(11):e79680. doi:39.10.1371/journal.pone.0079680. eCollection 2013.
41. Connes P, Lamarre Y, Waltz X, Ballas SK, Lemonne N, Etienne-Julan M, Hue O, Hardy-Dessources MD, Romana M. Haemolysis and abnormal haemorheology in sickle cell anaemia. *Br J Haematol.* 2014;165(4):564–72. doi:10.1111/bjh.12786.
42. Helm KF, Su WP, Muller SA, Kurtin PJ. Malignant lymphoma and leukemia with prominent ulceration, clinicopathologic correlation of 33 cases. *J Am Acad Dermatol.* 1992;27(4):553–9.
43. Suga H, Sugaya M, Yamamoto M, Miyagaki T, Ohmatsu H, Hoashi T, Sato S. Peripheral T cell lymphoma, not otherwise specified, showing multiple ulcers on the extremities. *Int J Dermatol.* 2013;52(9):1147–9.
44. Kempf W, Kazakov DV, Mitteldorf C. Cutaneous lymphomas, an update. Part 2: B-cell lymphomas and related conditions. *Am J Dermatopathol.* 2014;36(3):197–210.
45. Hasegawa M1, Nagai Y, Sogabe Y, Hattori T, Inoue C, Okada E, Tago O, Ishikawa O. Clinical analysis of leg ulcers and gangrene in rheumatoid arthritis. *J Dermatol.* 2013;40(12):949–54. doi:10.1111/1346-8138.12359.
46. Seitz CS, Berens N, Bröcker EB, Trautmann A. Leg ulceration in rheumatoid arthritis – an underreported multicausal complication with considerable morbidity: analysis of thirty-six patients and review of the literature. *Dermatology.* 2010;220(3):268–73. doi:10.1159/000284583.
47. Nishikawa JA. Are leg ulcers in rheumatoid arthritis due to vasculitis? *Eur J Rheumatol Inflamm.* 1983;6(3):288–90.
48. Ferreira MC, Tuma Jr P, Carvalho VF, Kamamoto F. Complex wounds. *Clinics (Sao Paulo).* 2006;61(6):571–8.
49. Gustilo RB, Anderson JT. Prevention of infection in the treatment of one thousand and twenty-five open fractures of long bones: retrospective and prospective analyses. *J Bone Joint Surg Am.* 1976;58(4):453–8.
50. Liu H, Wang L, Zhang Y, Yu Z, Liu Z, Li G, Zhao G, Hu K. Tissue transplantation with bone transmission for treating large defects of tibial bone and soft tissue. *Zhongguo Xiu Fu Chong Jian Wai Ke Za Zhi.* 2013;27(3):295–8.
51. Tascini C, Piaggese A, Tagliaferri E, Iacopi E, Fondelli S, Tedeschi A, Rizzo L, Leonildi A, Menichetti F. Microbiology at first visit of moderate-to-severe diabetic foot infection with antimicrobial activity and a survey of quinolone monotherapy. *Diabetes Res Clin Pract.* 2011;94(1):133–9.



52. Khanna AK, Tiwary SK, Kumar P, Khanna R, Khanna A. A case series describing 118 patients with lower limb necrotizing fasciitis. *Int J Low Extrem Wounds*. 2009;8(2):112–6.
53. Davis JM, Crawford PS. Persistent leg ulcers in an obese patient with venous insufficiency and elephantiasis. *J Wound Ostomy Continence Nurs*. 2002;29(1):55–60.
54. Karnasula VM. Management of ulcers in lymphoedematous limbs. *Indian J Plast Surg*. 2012;45(2):261–5.
55. Baveja CP, Gumma VN, Jain M, Jha H. Foot ulcer caused by multidrug-resistant *Mycobacterium tuberculosis* in a diabetic patient. *J Med Microbiol*. 2010;59(Pt 10):1247–9.
56. Chao YC, Chen CH, Chen YK, Chou CT. A large ulcer and cutaneous small-vessel vasculitis associated with syphilis infection. *Scand J Rheumatol*. 2006;35(2):147–51.
57. Grauwyn MY, Cartel JL, Lepers JP. How does one treat the osteitis and osteoarthritis of the extremities in older leprosy patients using granulated table sugar? *Acta Leprol*. 1999;11(4):147–52.
58. Cecilia-Matilla A, Lázaro-Martínez JL, Aragón-Sánchez J, García-Morales E, García-Álvarez Y, Beneit-Montesinos JV. Histopathologic characteristics of bone infection complicating foot ulcers in diabetic patients. *J Am Podiatr Med Assoc*. 2013;103(1):24–31.
59. Pilgrim W, Hayes R, Hanson DW, Zhang B, Boudreau B, Leonfellner S. Skin cancer (basal cell carcinoma, squamous cell carcinoma, and malignant melanoma): new cases, treatment practice, and health care costs in New Brunswick, Canada, 2002–2010. *J Cutan Med Surg*. 2014;18:1–12.
60. Wechsler RJ, Schilling JF. CT of the gluteal region. *AJR Am J Roentgenol*. 1985;144(1):185–90.
61. Fine A, Zacharias J. Calciphylaxis is usually non-ulcerating: Risk factors, outcome and therapy. *Kidney Int*. 2002;61:2210–7.
62. Zhou Q, Neubauer J, Kern JS, Grotz W, Walz G, Huber TB. Calciphylaxis. *Lancet*. 2014;383(9922):1067.
63. Emohare O, Kowal-Vern A, Wiley D, Latenser BA. Vacuum-assisted closure use in calciphylaxis. *J Burn Care Rehabil*. 2004;25(2):161–4.
64. Sharon V, Goodarzi H, Chambers CJ, Fung MA, Armstrong AW. Erythema induratum of Bazin. *Dermatol Online J*. 2010;16(4):1.
65. Teramura K, Fujimoto N, Nakanishi G, Shigeta M, Tanaka T. Disseminated erythema induratum of Bazin. *Eur J Dermatol*. 2014;24(6):697–8.
66. Davison S, Lee E, Newton ED. Martorell's ulcer revisited. *Wounds*. 2003;15(6):208–12.
67. Duncan HJ, Faris IB. Martorell's hypertensive ischemic leg ulcers are secondary to an increase in the local vascular resistance. *J Vasc Surg*. 1985;2:581–4.