

# The appendix and the inguinal canal: Amyand's hernia a case report

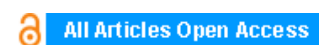
**Shariful Islam, Devin Hosein, Vinoo Bheem, Vijay Naraynsingh**

## ABSTRACT

**Introduction:** Inguinal hernia repairs are one of the most common operations performed by the general surgeon. Occasionally, an emergency repair must be performed in the setting of painful incarceration, strangulation or obstruction. It is, therefore, essential that sound knowledge of the anatomy of the inguinal canal and variants of the inguinal hernia are required. One such variant is an Amyand's hernia, a rare inguinal hernia defined by the presence of the appendix in the inguinal canal.

**Case Report:** We report a 52-year-old male who presented to our institution with a painful incarcerated right inguinal hernia who subsequently underwent emergency repair. A Type 1 Amyand's hernia was discovered on operation, an appendectomy and a Lichtenstein hernia repair were then performed. Due to the rarity of this hernia there are no standard guidelines for repair with respect to performing appendectomy or the use of mesh post appendectomy.

**Conclusion:** The aim of this report is to assist the surgeon in making an informed decision on treatment of this rarity by review of current literature.



## International Journal of Case Reports and Images (IJCRI)



International Journal of Case Reports and Images (IJCRI) is an international, peer reviewed, monthly, open access, online journal, publishing high-quality, articles in all areas of basic medical sciences and clinical specialties.

Aim of IJCRI is to encourage the publication of new information by providing a platform for reporting of unique, unusual and rare cases which enhance understanding of disease process, its diagnosis, management and clinico-pathologic correlations.

IJCRI publishes Review Articles, Case Series, Case Reports, Case in Images, Clinical Images and Letters to Editor.

**Website: [www.ijcasereportsandimages.com](http://www.ijcasereportsandimages.com)**

# The appendix and the inguinal canal: Amyand's hernia a case report

Shariful Islam, Devin Hosein, Vinoo Bheem, Vijay Naraynsingh

## ABSTRACT

**Introduction:** Inguinal hernia repairs are one of the most common operations performed by the general surgeon. Occasionally, an emergency repair must be performed in the setting of painful incarceration, strangulation or obstruction. It is, therefore, essential that sound knowledge of the anatomy of the inguinal canal and variants of the inguinal hernia are required. One such variant is an Amyand's hernia, a rare inguinal hernia defined by the presence of the appendix in the inguinal canal. **Case Report:** We report a 52-year-old male who presented to our institution with a painful incarcerated right inguinal hernia who subsequently underwent emergency repair. A Type 1 Amyand's hernia was discovered on operation, an appendectomy and a Lichtenstein hernia repair were then performed. Due to the rarity of this hernia there are no standard guidelines for repair with respect to performing appendectomy or the use of mesh post appendectomy. **Conclusion:** The aim of this report is to assist the surgeon in making an

**informed decision on treatment of this rarity by review of current literature.**

**Keywords:** Inguinal hernia, Amyand's hernia, mesh repair

### How to cite this article

Islam S, Hosein D, Bheem V, Naraynsingh V. The appendix and the inguinal canal: Amyand's hernia a case report. Int J Case Rep Images 2015;6(10):636–639.

doi:10.5348/ijcri-2015104-CR-10565

## INTRODUCTION

Hernia repairs are one of the most common operations done by the general surgeon with inguinal hernias being the most common type of abdominal wall hernias [1]. Inguinal hernias often present as acute emergencies and require emergent repair, therefore extensive knowledge of the anatomy and the variants of hernias is essential. An Amyand's hernia is one such variant of an inguinal hernia. This rare type of hernia is characterized by the presence of the appendix in the inguinal canal. Amyand's hernia can be further classified by the presence of co-existing pathology involving the appendix, that is, whether the appendix is inflamed or if there is unrelated pathology associated with the hernia [2].

The first case of an appendix within the inguinal sac was described by Claudius Amyand and published in the Philosophical Transactions of the Royal Society of London in 1776 [3]. He is also credited with performing the first successful appendectomy [3].

It is, therefore, important that awareness of this hernia and appropriate treatment of this rarity be kept in mind by every surgeon performing a hernia repair.

Shariful Islam<sup>1</sup>, Devin Hosein<sup>1</sup>, Vinoo Bheem<sup>2</sup>, Vijay Naraynsingh<sup>3</sup>

**Affiliations:** <sup>1</sup>Senior House Officer, Surgery, San Fernando Teaching Hospital, Trinidad & Tobago; <sup>2</sup>Head of the Department of Surgery (Ag), San Fernando Teaching Hospital, Trinidad & Tobago; <sup>3</sup>Department of Clinical Surgical Sciences, University of the West Indies, St Augustine, Trinidad and Tobago.

**Corresponding Author:** Dr. Shariful Islam, MBBS, DM (Surgery), Registrar in General Surgery, San Fernando Teaching Hospital, Trinidad & Tobago; E-mail: shar\_islam7@hotmail.com

Received: 08 July 2015

Accepted: 26 August 2015

Published: 01 October 2015

## CASE REPORT

A 52-year-old male presented to the emergency department with sudden onset right sided groin pain and swelling. He is a construction worker by occupation and has been diagnosed with a right sided inguinal hernia one year prior. He has missed his date for surgery on several occasions. The pain was localized to the hernia which was irreducible. He had one episode of vomiting with no other symptoms of intestinal obstruction. He has a 30-pack year smoking history with no chronic cough or any urinary symptoms.

On examination his abdomen was soft, with tenderness localized to right inguinal region and no signs of intestinal obstruction or peritonism. The hernia was tender, irreducible and no cough impulse was elicited. External genitals and rectal examinations were unremarkable.

Hematological investigations, chest and abdominal X-rays were unremarkable. The patient was scheduled for emergency hernia repair.

Findings on operation included sliding hernia with non-inflamed appendix in the inguinal canal (Figures 1 and 2) consistent with a Type 1 Amyand's hernia [4]. Appendectomy was performed and a macro-porous polypropylene mesh was placed via Lichtenstein method. The patient did well and was discharged day 1 post operation with prophylactic antibiotics. Histology revealed the appendix was not inflamed confirming the patient had a Type 1 Amyand's hernia [4]. The patient was followed-up in the surgical outpatient clinic and at sixth month follow-up he recovered fully.

## DISCUSSION

Amyand's hernia is defined as the presence of the appendix in the inguinal canal. It accounts for less than 1% of all inguinal hernias [5]. Appendicitis occurring within the inguinal canal is even a rarer clinical entity [6, 7]. It almost always occurs on the right, however, there are a few cases of it occurring on the left [8, 9].

Amyand's hernia can be classified into different

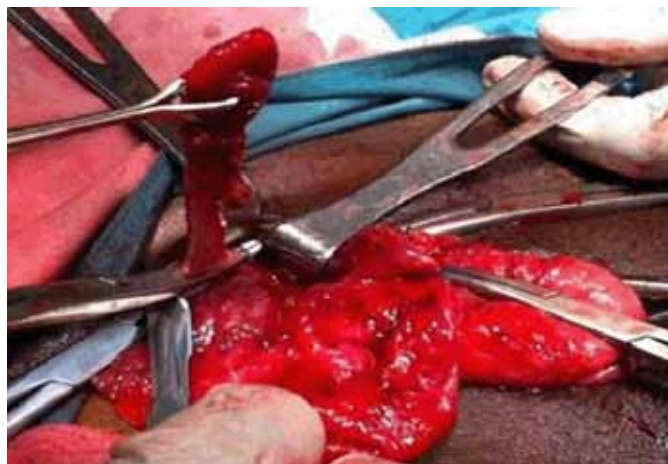


Figure 2: Appendectomy being performed through herniotomy.

subtypes. The classification was put forward by Losanoff and Basson and incorporates the presence of co-existing pathology with the hernia. According to the classification, there are four different types [4].

Type 1 is the presence of a non-inflamed appendix in the inguinal canal.

Type 2 acute appendicitis in the inguinal canal without abdominal wall sepsis.

Type 3 acute appendicitis in the inguinal canal with abdominal wall sepsis.

Type 4 acute appendicitis in the inguinal canal and related or unrelated abdominal pathology.

Based on this classification, our patient had a Type 1 Amyand's hernia.

How can we diagnose the presence of an Amyand's hernia preoperatively? Amyand's hernia is diagnosed almost exclusively intraoperatively, however, there are a few cases where the diagnosis was made preoperatively. In these cases, this was done via the use of radiological investigations [10]. Having obtained the diagnosis of Amyand's hernia, how should one proceed? What is considered best management? Should the appendix be removed in a Type 1 hernia? Can we safely use mesh after performing an appendectomy? Amyand's hernia, being a rarity, presents a dilemma in terms of management as there is insufficient evidence to come to a definite conclusion.

In our case, the appendix was not inflamed and an appendectomy was performed. Some authors may choose not to remove the appendix [7, 11]. However, it is our belief that the appendix should be always removed in all Types of Amyand's hernia. If reduction of the appendix is performed, excessive manipulation may result in compromise of its blood supply therefore one may be reducing a compromised visceral structure. In addition, on reduction adhesions will develop between the appendix and the deep ring which will, in the event appendicitis develops, the presentation will be atypical. To further argue the point that appendectomy should be done in Type 1 Amyand's hernia, if one simply reduces the appendix and applies a mesh, the local inflammatory

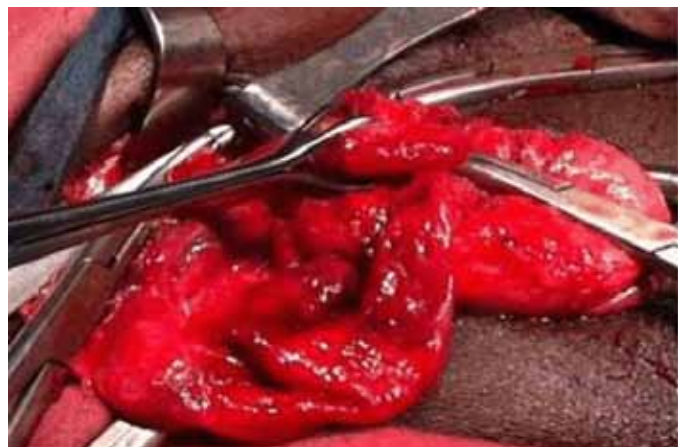


Figure 1: Appendix in the inguinal canal with Babcock placed on the appendix.

response produced by the mesh can induce an appendicitis [12]. Conversely, an unrelated appendicitis can result in a severe mesh infection [13].

The issue of using a prosthetic mesh after appendectomy in an Amyand's hernia is a tenuous one. The benefits of performing a mesh repair of a hernia are well documented. Mesh repairs are associated with lower rates of recurrence compared to non-mesh repairs [14]. A review of 13 trials compared open hernia repairs with and without mesh found a significantly lower risk of recurrent hernia with mesh repairs [14]. In addition, the EU Hernia Trialists Collaboration reviewed 8221 patients and concluded a significantly higher recurrence rate for hernias repaired without mesh versus those performed with mesh using either open or laparoscopic techniques [15].

In our case, the patient is at increased risk for recurrence because of his occupation. Also, the appendix was noninflamed, therefore, mesh should be used. In type 2 and type 4 Amyand's hernias, appendectomy should be performed and mesh can be used depending on the amount of spillage at appendectomy and condition of surrounding tissues. In Type 3 Amyand's hernia, appendectomy should be performed however, mesh use, may not be indicated. There are cases where mesh has been used in infected tissue, however, we do not recommend this practice [16].

Finally, no discussion about Amyand's hernia is complete without brief mention of its femoral counterpart. A De Garengeot hernia is a rare subtype of femoral hernia in which the appendix lies within a femoral hernia [17]. Similarly to an Amyand's hernia, it presents its own diagnostic and therapeutic challenges that only a few surgeons had the honor of encountering.

## CONCLUSION

Hernias repairs are routine operations done by the general surgeon, however, one must be aware of the rare variants. For the patient with the Amyand's hernia, the decision to perform an appendectomy and mesh repair should ultimately be individualized to each patient.

\*\*\*\*\*

## Acknowledgements

Informed consent was obtained from the patient to publish this case.

## Author Contributions

Shariful Islam – Substantial contributions to conception and design, Acquisition of data, Analysis and interpretation of data, Drafting the article, Revising it critically for important intellectual content, Final approval of the version to be published

Devin Hosein – Analysis and interpretation of data,

Revising it critically for important intellectual content, Final approval of the version to be published  
Vinoobheem – Analysis and interpretation of data, Revising it critically for important intellectual content, Final approval of the version to be published  
Vijay Naraynsingh – Analysis and interpretation of data, Revising it critically for important intellectual content, Final approval of the version to be published

## Guarantor

The corresponding author is the guarantor of submission.

## Conflict of Interest

Authors declare no conflict of interest.

## Copyright

© 2015 Shariful Islam et al. This article is distributed under the terms of Creative Commons Attribution License which permits unrestricted use, distribution and reproduction in any medium provided the original author(s) and original publisher are properly credited. Please see the copyright policy on the journal website for more information.

## REFERENCES

1. Dabbas N, Adams K, Pearson K, Royle G. Frequency of abdominal wall hernias: is classical teaching out of date? *JRSM Short Rep* 2011 Jan 19;2(1):5.
2. Holzheimer RG. Inguinal Hernia: classification, diagnosis and treatment--classic, traumatic and Sportsman's hernia. *Eur J Med Res* 2005 Mar 29;10(3):121–34.
3. Amyand C. Of an inguinal rupture, with a pin in the appendix caeci, incrusted with stone; and some observations on wounds in the guts. *Philos Trans R Soc London* 1736;39:329–36.
4. Losanoff JE, Basson MD. Amyand hernia: a classification to improve management. *Hernia* 2008 Jun;12(3):325–6.
5. Thomas WE, Vowles KD, Williamson RC. Appendicitis in external herniae. *Ann R Coll Surg Engl* 1982 Mar;64(2):121–2.
6. Salemis NS, Nisotakis K, Nazos K, Stavrinou P, Tsohataridis E. Perforated appendix and periappendicular abscess within an inguinal hernia. *Hernia* 2006 Dec;10(6):528–30.
7. D'Alia C, Lo Schiavo MG, Tonante A, et al. Amyand's hernia: case report and review of the literature. *Hernia* 2003 Jun;7(2):89–91.
8. Gupta S, Sharma R, Kaushik R. Left-sided Amyand's hernia. *Singapore Med J* 2005 Aug;46(8):424–5.
9. Weber RV, Hunt ZC, Kraal JG. Amyand's hernia: Etiologic and therapeutic implications of the two complications. *Surg Rounds* 1999;22:552–6.
10. Maizlin ZV, Mason AC, Brown C, Brown JA. CT findings of normal and inflamed appendix in groin hernia. *Emerg Radiol* 2007 Jun;14(2):97–100.
11. Sharma H, Gupta A, Shekhawat NS, Memon B, Memon MA. Amyand's hernia: a report of 18

- consecutive patients over a 15-year period. *Hernia* 2007 Feb;11(1):31–5.
12. Jennings JM, Ng PCh. Laparoscopic appendicectomy for suspected mesh-induced appendicitis after laparoscopic transabdominal preperitoneal polypropylene mesh inguinal herniorrhaphy. *J Minim Access Surg* 2010 Jan;6(1):19–21.
  13. Sebbag G, Ovnat A, Shaked G, Dukhno O, Levy I. Severe mesh graft infection consecutive to a perforated acute appendicitis 8 years after transabdominal laparoscopic right inguinal hernia repair: A review of the literature. *J Pelvic Med Surg* 2005;11:275–7.
  14. Scott NW, McCormack K, Graham P, Go PM, Ross SJ, Grant AM. Open mesh versus non-mesh for repair of femoral and inguinal hernia. *Cochrane Database Syst Rev* 2002;(4):CD002197.
  15. EU Hernia Trialists Collaboration. Mesh compared with non-mesh methods of open groin hernia repair: systematic review of randomized controlled trials. *Br J Surg* 2000 Jul;87(7):854–9.
  16. Guzzo JL, Bochicchio GV, Henry S, Keller E, Scalea TM. Incarcerated inguinal hernia in the presence of Fournier's gangrene: a novel approach to a complex problem. *Am Surg* 2007 Jan;73(1):93–5.
  17. De Garengéot RJC. *Traite des operations de chirurgie*. 2nd ed. Paris: Huart; 1731. p. 369–71.

Access full text article on  
other devices



Access PDF of article on  
other devices



## Edorium Journals: An introduction

Edorium Journals Team

### About Edorium Journals

Edorium Journals is a publisher of high-quality, open access, international scholarly journals covering subjects in basic sciences and clinical specialties and subspecialties.

#### Invitation for article submission

We sincerely invite you to submit your valuable research for publication to Edorium Journals.

### But why should you publish with Edorium Journals?

In less than 10 words - we give you what no one does.

#### Vision of being the best

We have the vision of making our journals the best and the most authoritative journals in their respective specialties. We are working towards this goal every day of every week of every month of every year.

#### Exceptional services

We care for you, your work and your time. Our efficient, personalized and courteous services are a testimony to this.

#### Editorial Review

All manuscripts submitted to Edorium Journals undergo pre-processing review, first editorial review, peer review, second editorial review and finally third editorial review.

#### Peer Review

All manuscripts submitted to Edorium Journals undergo anonymous, double-blind, external peer review.

#### Early View version

Early View version of your manuscript will be published in the journal within 72 hours of final acceptance.

#### Manuscript status

From submission to publication of your article you will get regular updates (minimum six times) about status of your manuscripts directly in your email.

### Our Commitment

#### Six weeks

You will get first decision on your manuscript within six weeks (42 days) of submission. If we fail to honor this by even one day, we will publish your manuscript free of charge.

#### Four weeks

After we receive page proofs, your manuscript will be published in the journal within four weeks (31 days). If we fail to honor this by even one day, we will publish your manuscript free of charge and refund you the full article publication charges you paid for your manuscript.

### Most Favored Author program

Join this program and publish any number of articles free of charge for one to five years.

### Favored Author program

One email is all it takes to become our favored author. You will not only get fee waivers but also get information and insights about scholarly publishing.

### Institutional Membership program

Join our Institutional Memberships program and help scholars from your institute make their research accessible to all and save thousands of dollars in fees make their research accessible to all.

### Our presence

We have some of the best designed publication formats. Our websites are very user friendly and enable you to do your work very easily with no hassle.

### Something more...

We request you to have a look at our website to know more about us and our services.

We welcome you to interact with us, share with us, join us and of course publish with us.



Edorium Journals: On Web



Browse Journals

CONNECT WITH US

