

## CASE REPORT



# The Use of Autologous Platelet Rich Plasma as an adjunct for chronically infected wounds in the Orthopaedic Patient –A case report of first clinical experience

Shiva Chackan<sup>1</sup> | Shariful Islam<sup>2\*</sup> | Trevor Seepaul<sup>3</sup> | Vijay Naraynsingh<sup>4</sup>

<sup>1</sup>Orthopaedic Department, San Fernando Teaching Hospital, Trinidad and Tobago and Department of Clinical Surgical Science, University of the West Indies. St. Augustine, Trinidad and Tobago

<sup>2</sup>Department of General Surgery, San Fernando Teaching Hospital, Trinidad and Tobago and Department of Clinical Surgical Science, University of the West Indies. St. Augustine, Trinidad and Tobago

<sup>3</sup>Orthopaedic Department, San Fernando Teaching Hospital, Trinidad and Tobago and Department of Clinical Surgical Science, University of the West Indies. St. Augustine, Trinidad and Tobago

<sup>4</sup>Department of Clinical Surgical Science, University of the West Indies. St. Augustine, Trinidad and Tobago

### Abstract

Chronic Orthopaedic infections and the wounds that accompany them make up a large percentage of Orthopaedic complications that are seen in low resource settings such as ours at the San Fernando General Hospital. Autologous Platelet Rich Plasma has shown relatively good results in the treatment of chronic wounds. However, its role in the treatment of chronically infected wounds after the removal of orthopaedic implants is yet to be explored. This case report analyses and examines the rate of healing of a relatively large ulcer post removal of an infected Orthopaedic implant. Following surgical debridement the wound was treated with PRP and this paper represents the first post surgical wound treated with PRP at our tertiary hospital.

Keywords: Platelet rich plasma (PRP), Chronic infected orthopaedic wound, Wound healing

## 1 | INTRODUCTION

Platelet Rich Plasma (PRP) is a plasma platelet concentrate derived from centrifugation of autologous whole blood. PRP has been used since the 1950's in the treatment of various condi-

tions across various specialties<sup>1</sup> and has been shown to enhance and accelerate both soft and hard tissue healing<sup>2-4</sup>. Conventional therapies such as surgical debridement, wound dressings and even skin grafts or flaps often fail to resolve poor wound healing. This is especially so since, in the presence of acute

# THE USE OF AUTOLOGOUS PLATELET RICH PLASMA AS AN ADJUNCT FOR CHRONICALLY INFECTED WOUNDS IN THE ORTHOPEDIC PATIENT –A CASE REPORT OF FIRST CLINICAL EXPERIENCE

of chronic infections, these treatments are unable to provide the necessary growth factors<sup>5</sup>. PRP has been shown to contain Growth Hormone (GH), Platelet Derived Growth Factor (PDGF), Epidermal Growth Factor (EGF), Fibroblast Growth Factor (FGF) and Transforming Growth Factor - Beta (TGF- $\beta$ ) which all help to increase

the rate of wound healing<sup>2</sup>. Tendon and muscle repairs have shown good results<sup>3</sup>. The reversal of conventional skin ulcers have also been reported<sup>3</sup>. The use of PRP has been documented, to be effective in treatment of arterial and venous ulcers which showed minimal healing initially<sup>3</sup>. No major complications have been documented with the use of Autologous PRP for wounds dressings<sup>6-7</sup>. PRP basically functions as a tissue sealant and drug delivery system<sup>6</sup>.

In the treatment of acute or even chronically infected wounds such as our index patient, PRP has been shown to significantly decrease rates of superficial and deep infections as compared to the control group<sup>6</sup>. In this paper we examine the impact of PRP dressings in the treatment of a chronically infected wound.

## 2 | CASE REPORT

The patient is a 50 year old male with a known history of Bipolar Disorder controlled on Amitriptyline and Trifluoperazine with no further medical comorbidities. Of note he consumed alcohol in moderation with normal pre-operative liver function tests. He did not smoke cigarettes or illegal substances.

**Supplementary information** The online version of this article (<https://doi.org/10.15520/ijmhs.v10i11.3134>) contains supplementary material, which is available to authorized users.

**Corresponding Author:** *Shariful Islam*  
*Department of General Surgery, San Fernando Teaching Hospital, Trinidad and Tobago and Department of Clinical Surgical Science, University of the West Indies. St. Augustine, Trinidad and Tobago*  
*Email: [sssl201198@yahoo.com](mailto:sssl201198@yahoo.com).*

In March 2014, he sustained a severe twisting injury to his right leg. Upon presentation to our hospital, plain radiographs of the leg showed a Comminuted Spiral Fracture of the Distal  $\frac{1}{3}$  of the Right Tibia and Fibula with syndesmotic widening. There were no signs of an open wound or any neuro-vascular deficits. However, there was extensive soft tissue swelling. Initial Orthopedic management consisted of:

- i) Application of an incomplete Plaster of Paris cast for immobilization.
- ii) Oral analgesia.
- iii) Admission to the ward for urgent surgical reduction and fixation under general anaesthesia.

A prophylactic dose of antibiotics (Cefuroxime 1.5g IV) was administered 30 minutes prior to the skin incision.

The intra-operative fixation included:

- i) Closed intramedullary nailing of the Right Tibia with proximal and distal locking screws.
- ii) Reduction of the Fibula fracture and fixation with a  $\frac{1}{3}$  Tubular plate and screws.
- iii) Stabilization of the syndesmosis with placement of a syndesmotic screw across three cortices.
- iv) Tourniquet time aggregated to 86 minutes at 300mm of Hg.

The entire operation was completed under fluoroscopic guidance.

He had a normal operative and post operative course. Physiotherapy was commenced 1 day post surgery. Haemoglobin levels remained above 10mg/dl (Pre-op - 12.6mg/dl, Post-op - 10.9mg/dl) throughout. He was discharged post operatively after completion of

- i) Post- Operative antibiotics, amounting to 6 doses (Co-Amoxiclav 1.2g IV TDS)
- ii) Change of dressing and examination of the wound.
- iii) Post Operative supplementation of the internal fixation with a Below Knee Back Slab
- iv) Post Operative X-rays

He was reviewed in our fracture clinic at 2 weeks post surgery. At this time physical examination showed a discharging ulcer 2cm x 3cm at the anterior midline knee incision. He was afebrile and did not

DAY	Pre - Operative	Post Operative D1	D5	D9	D11	D 14
C - Reactive Protein (mg/l)	83	96	74	43	19	6
White Cell Count (x 10 <sup>9</sup> /L)	18.1	18.4	14.7	11.2	9.4	8.6

*"Table 1. Table showing the trend of CRP and WCC Post Removal of Infected Tibial Nail and Fibula Plate with Autologous PRP Dressings."*

### FIGURE 1:

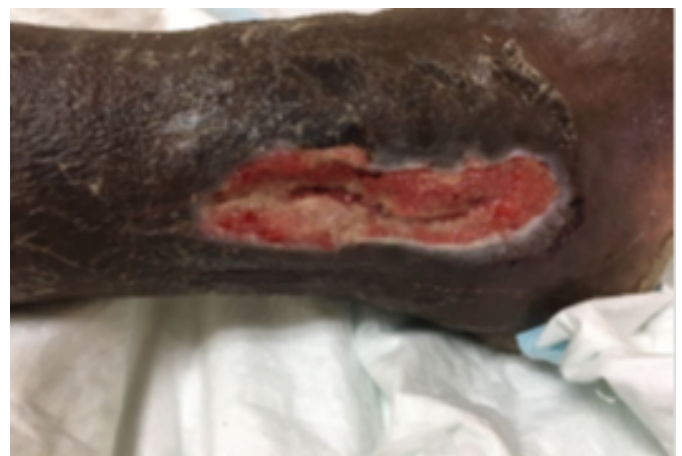give a history of chills or rigours. Haematological investigations revealed an elevated C- Reactive Protein (CRP) (18.4mg/l) and Erythrocyte Sedimentation Rate (ESR) (95mm/hr) but a normal White Blood Count (WBC) (7.3 x. 10<sup>9</sup>/ml) and Haemoglobin (Hb) (12.4mg/dl). He was readmitted to the ward and intravenous antibiotics restarted with daily dry, sterile dressings. Wound swab taken on the day he presented revealed E.Coli bacteria sensitive to Co-amoxiclav. This antibiotic was continued for 1 week and his inflammatory markers showed a downward trend. The patient was discharged 7 days later with a clean healing ulcer. His inflammatory markers on the final day of admission showed CRP (9mg/l) and ESR (5mm/hr) [Table 1]. He was continued on oral antibiotics. Ward reviews were completed every 2 weeks following discharge for 2 visits. These visits revealed a healing ulcer with no recurrent infection and normal inflammatory markers [Table 1]. He was then discharged to the Orthopaedic Outpatient Clinic for bi-monthly appointments. He was discharged 1 year later with a fully epithelialized wound.

In August 2017, the patient presented to our Accident and Emergency Department. He complained of a swollen painful right lower limb. Examination revealed a fluctuant swelling over the right lateral malleolus and a similar swelling over the proximal tibial locking screw site. Both sites showed a discharge of purulent material. A tentative diagnosis of an infected Intramedullary Tibial Nail and Fibular Plate was made. This was supported by plain radiographs which showed osteolysis of the Tibial shaft and lower 1/3 of the Fibula in close proximity to the plate and screws. These X-rays also revealed complete fracture union with callus formation at both the Tibial and Distal Fibula Fracture sites. Wound Swabs were taken and empiric broad spectrum antibiotics

(Co-Amoxiclav) started in light of clinical picture. Haematological investigations of WBC (18.4 x 10<sup>9</sup>) showed a Neutrophilia of 83%. The patient underwent urgent removal of the infected implants and surgical debridement of both wounds.

A large 10cm x 4cm x 4cm ulcer was present post operatively over the lateral malleolus with the Fibula exposed [Figure1]. Autologous PRP dressings were applied to the open ulcer every two days starting on post operative day 1 and continued for 14 days using a process outlined below:

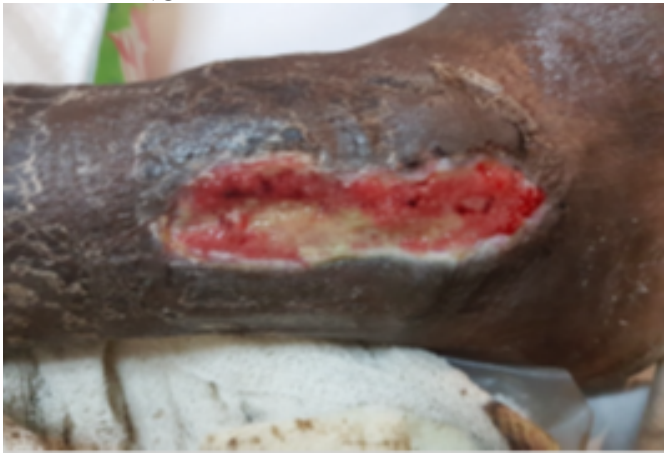- I. Outer aspect of the wound was cleaned with 70% Hibitane in Alcohol.
- II. 20mls of blood was obtained via venepuncture from the antecubital fossa under aseptic conditions using a large bore needle i.e. >20G.
- III. Whole blood was centrifuged for 6 minutes at 1700 RPM.
- IV. Supernatant and plasma were removed from red blood cells by aspiration and allowed to sit after mixing with 1ml Calcium Chloride until gel formed.
- V. Gel applied to wound and covered with sterile dry dressing.
- VI. Dressing changed every two days by Medical officer with photographs and measurement of wound at each stage.



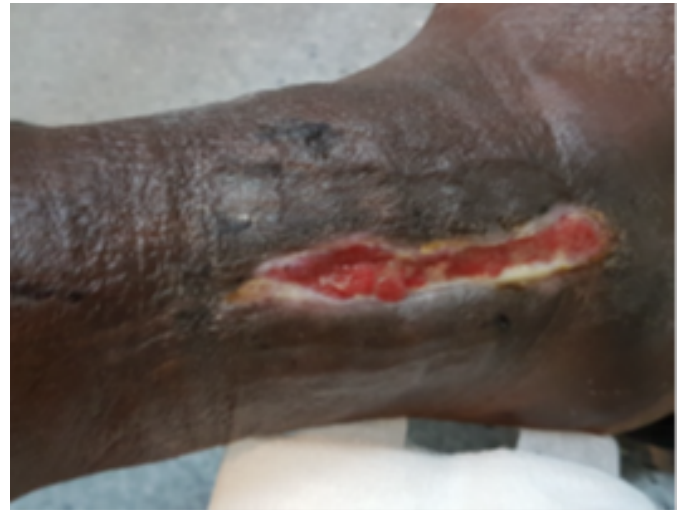**FIGURE 2: Day One Post Removal of Infected Implant with Autologous PRP Dressings**

During his 2 week in-patient stay intravenous antibiotics were continued. CRP and wound swabs were repeated every 4 days. Wound swab results noted; No

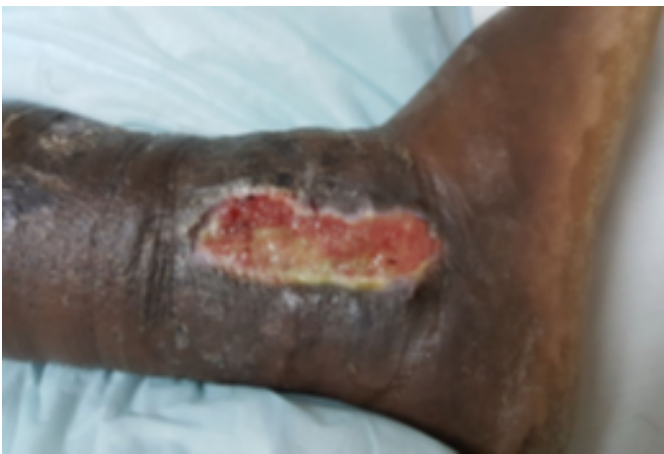THE USE OF AUTOLOGOUS PLATELET RICH PLASMA AS AN ADJUNCT FOR CHRONICALLY INFECTED WOUNDS IN THE ORTHOPEDIC PATIENT –A CASE REPORT OF FIRST CLINICAL EXPERIENCE



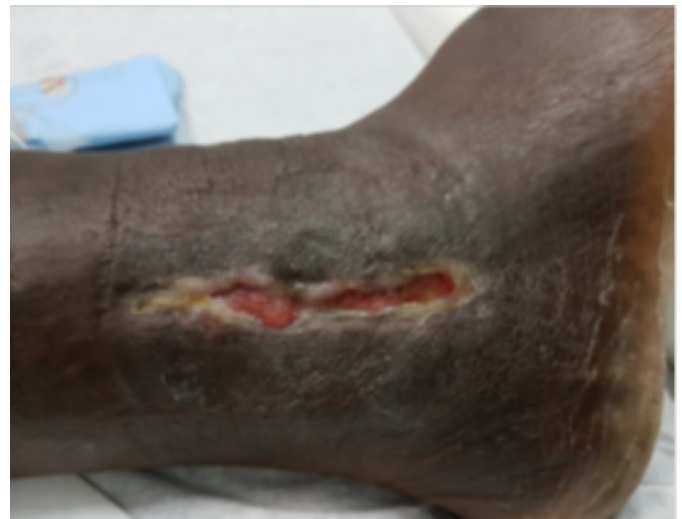**FIGURE 3: Day Three Post Removal of Infected Implant with Autologous PRP Dressing.**



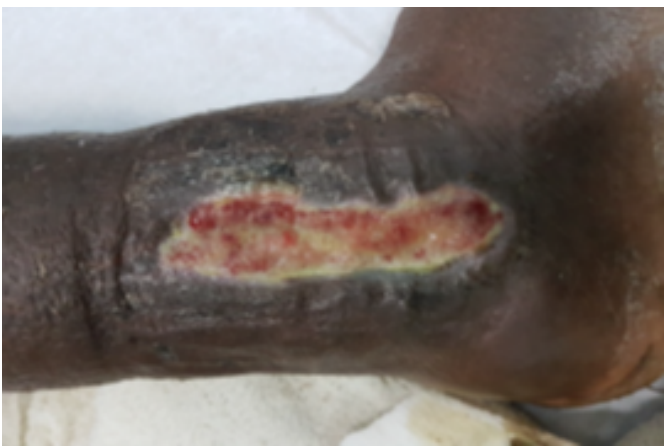**FIGURE 6: Day Eleven Post Removal of Infected Implant with Autologous PRP Dressings**



**FIGURE 4: Day Five Post Removal of Infected Implant Autologous PRP Dressings**



**FIGURE 7: Day Thirteen Post Removal of Infected Implant with Autologous PRP Dressings**



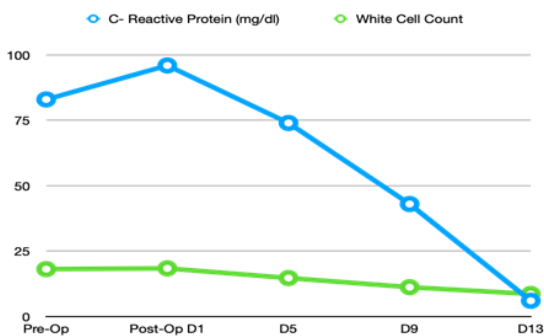
**FIGURE 5: Day Seven Post Removal of Infected Implant with Autologous PRP Dressings**

Bacterial Growth and CRP and WBC result trends are noted in Graph 1.

The size of the wound gradually decreases and complete epithelialization of the wound occurred at day 14 [Figure 2-6 & Graph 2] and the patient was discharged home after 2 days.

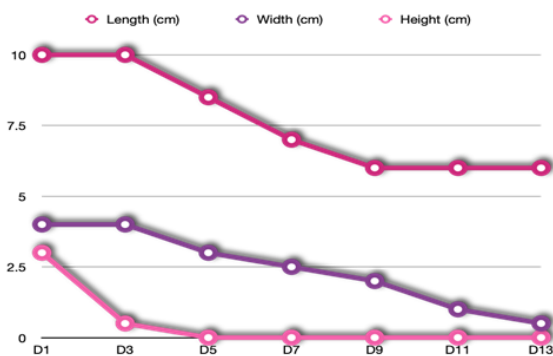
### **3 | DISCUSSION**

Wound healing especially in the presence of infection is particularly problematic especially in low resource settings. Chronically infected wounds creates



"Graph 1. Line Graph showing the trend of WCC and CRP Post Removal of Infected Tibial Nail and Fibula Plate with Autologous PRP Dressings."

FIGURE 8:



"Graph 2. Line Graph showing Trend of Wound Size Post Removal of Infected Tibial Nail and Fibula Plate with Autologous PRP Dressings."

FIGURE 9:

non-healing ulcers which pose significant morbidity in the untreated. The normal wound healing processing is a dynamic and complex entity encompassing 3 phases; inflammation, tissue formation and tissue remodelling which in the presence of infection can be disrupted at any stage<sup>8</sup>. Autologous PRP has a known role in the treatment of wounds intra-operatively and in the early post operative period<sup>2</sup> due to the sustained release of various growth factors which promote tissue repair and angiogenesis<sup>2-3</sup>. However their role as an antimicrobial agent in the treatment of infected wounds is largely de novo.

Our index patient featured a chronically infected wound with E.Coli sepsis for over 2 years. His clinical condition required surgical debridement and removal of the infected Orthopaedic implants according to basic principles. After implant removal at surgery clinical examination revealed stability of the fractures. This resulted in a large wound with exposed periosteum. There was a positive wound culture indicative of sepsis even in the absence of systemic hindrances to healing. A decision for the application of prophylactic Autologous PRP dressings

was taken on day 1 post operatively based on the recent meta-analysis examining 24 papers over the past 10 years which revealed the the reduced presence of infection in wounds treated with Autologous PRP<sup>9</sup>. The antimicrobial effect of platelets particularly against skin organisms<sup>10</sup> was demonstrated in our case indicated by a consistently negative wound culture from day 3 post operatively and a rapid decline of inflammatory markers after the use of Autologous PRP gel dressings<sup>10</sup>.

## 4 | CONCLUSION

Autologous PRP may be a useful adjunct in the acceleration of healing of chronically infected Orthopaedic wounds. This is supported by the results in this particular patient. PRP helps to create an internal biological environment most suited for restoration of tissue homeostasis by providing numerous cytokines and growth factors important in the regulation of inflammation, angiogenesis, synthesis and remodelling of new tissue. Its safety, cost effectiveness and autologous nature create minimal long term complications and reproducibility.

**Ethical approval:** No ethical approval is required to publish this case report.

**Author contribution:** All authors have contributed significantly in designing and organizing to write manuscript, collecting data as well help in critical analysing the manuscript. All authors have approved the final version of this manuscript

**Conflicts of interest:** The authors declare no conflicts of interest.

**Funding:** No fund was received to publish this article.

**Consent:** Informed consent was obtained from the parents for publication of this article.

**Guarantor:** The corresponding author will accept the full responsibility for the work. (1-10)

## REFERENCES

1. Anitua E; 2003.

THE USE OF AUTOLOGOUS PLATELET RICH PLASMA AS AN ADJUNCT FOR CHRONICALLY INFECTED WOUNDS IN THE ORTHOPEDIC PATIENT –A CASE REPORT OF FIRST CLINICAL

EXPERIENCE

2. Menta S, Watson JT. Platelet Rich Concentrate: Basic Science and Current Clinical Applications. *Journal of Orthopaedic Trauma*. 2008;22(6):432–438. Available from: <https://dx.doi.org/10.1097/bot.0b013e31817e793f>. doi:10.1097/bot.0b013e31817e793f.
3. Carter MJ, Fyelling CP, Parnell LK. Use of platelet rich plasma gel on wound healing: a systematic review and meta-analysis. *Eplasty*. 2011;.
4. Adler SC, Kent KJ. Enhancing wound healing with growth factors. *Facial Plastic Surgery Clinics of North America*. 2002;10(2):129–146. Available from: [https://dx.doi.org/10.1016/s1064-7406\(02\)00005-6](https://dx.doi.org/10.1016/s1064-7406(02)00005-6). doi:10.1016/s1064-7406(02)00005-6.
5. Suthar M, Gupta S, Bukhari S, Ponemone V. Treatment of chronic non-healing ulcers using autologous platelet rich plasma: a case series. *Journal of Biomedical Science*. 2017;24(1). Available from: <https://dx.doi.org/10.1186/s12929-017-0324-1>. doi:10.1186/s12929-017-0324-1.
6. Lacci MK, Dardik A. Platelet-rich plasma: support for its use in wound healing. *Yale J Biol Med*. 2010;p. 2844688–2844688.
7. Molloy T, Wang Y, Murrell GAC. The Roles of Growth Factors in Tendon and Ligament Healing. *Sports Medicine*. 2003;33(5):381–394. Available from: <https://dx.doi.org/10.2165/00007256-200333050-00004>. doi:10.2165/00007256-200333050-00004.
8. Andia I, Abate M. Platelet-rich plasma: underlying biology and clinical correlates. *Regenerative Medicine*. 2013;8(5):645–658. Available from: <https://dx.doi.org/10.2217/rme.13.59>. doi:10.2217/rme.13.59.
9. Martinez-Zapata M, José. Autologous platelet-Rich plasma for treating chronic wounds. *Cochrane Database of Systematic Reviews*. 2012;.
10. Smith SE, Roukis TS. Bone and Wound Healing Augmentation with Platelet-Rich Plasma. *Clinics in Podiatric Medicine and Surgery*. 2009;26(4):559–588. Available from: <https://dx.doi.org/10.1016/j.cpm.2009.07.002>. doi:10.1016/j.cpm.2009.07.002.

---

**How to cite this article:** Chackan S., Islam S., Seepaul T., Naraynsingh V. The Use of Autologous Platelet Rich Plasma as an adjunct for chronically infected wounds in the Orthopedic Patient –A case report of first clinical experience. *Innovative Journal of Medical and Health Science*. 2020;1349–1354. <https://doi.org/10.15520/ijmhs.v10i11.3134>

---