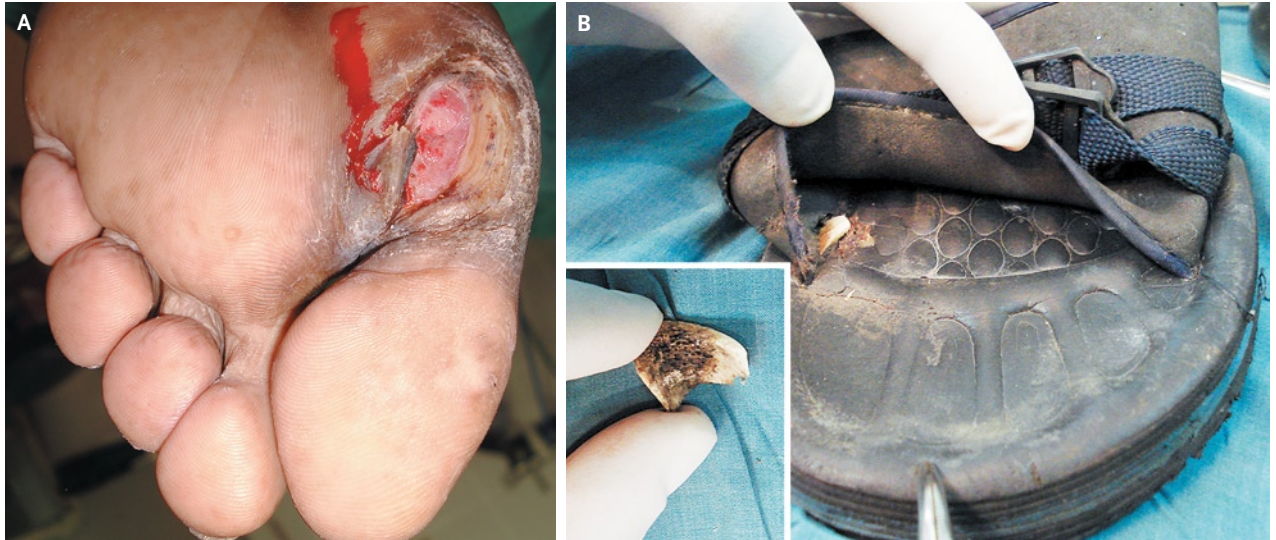


IMAGES IN CLINICAL MEDICINE

Neuropathic Ulceration



Surujpal Teelucksingh, M.D.
Vijay Naraynsingh, M.D.

University of the West Indies
St. Augustine, Trinidad and Tobago
pteelucksingh@gmail.com

A 61-YEAR-OLD MAN WITH A 15-YEAR HISTORY OF DIABETES AND RESULTING foot neuropathy presented with an ulcer of 3 months' duration overlying the first metatarsal head (Panel A). He was unaware of any recent foot trauma. He usually wore rubber slippers. Close inspection of his footwear revealed that an inconspicuous foreign body was lodged in the area of the slipper underlying the ulcer (Panel B and inset). The patient had been unable to sense the presence of the object against his foot because of his neuropathy. The foreign body was removed, and 6 weeks later the ulcer had healed completely. Ill-fitting footwear and soft-soled footwear penetrated by foreign objects are recognized sources of trauma to neuropathic feet. Regular inspection of feet and footwear is essential to minimize this risk.

Copyright © 2010 Massachusetts Medical Society.