

## Lateral Approach to the Profunda Femoris Artery

Vijay Naraynsingh, MD, Albany, New York  
Allastair M. Karmody, MD, Albany, New York  
Robert P. Leather, MD, Albany, New York  
John D. Corson, MD, FRCS, Albany, New York

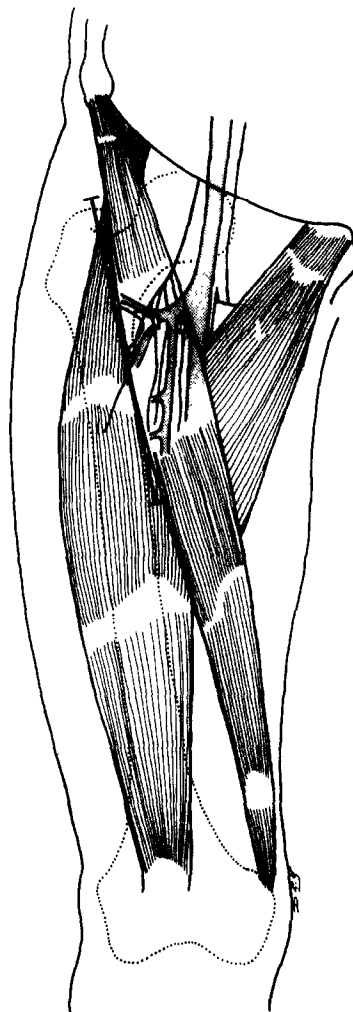
Graft infection, scarring from previous reconstructions, or radiation to the groin may prohibit a direct approach to the femoral vessels. In these circumstances, we have found a lateral approach to the profunda femoris artery to be useful. This approach obviates the need for a difficult dissection and permits placement of a graft in a clean area, leaving a layer of fascia and the sartorius muscle between the graft and the site of infection.

### Technique

An incision is made along the lateral border of the sartorius muscle, 6 cm lateral to the femoral pulse (Figure 1). The incision is continued through the deep fascia, and the sartorius muscle is retracted medially. Dissection along the medial border of the rectus femoris muscle will reveal the lateral circumflex femoral vessels, the vein being the more obvious. At this point, one or two branches of the femoral nerve, running superficial to these vessels, should be visualized, preserved, and drawn laterally. The dissection is then continued medially following the lateral circumflex vessels to the main trunk of the profunda femoris artery. Sufficient length of the profunda artery can now be exposed for an anastomosis. It is usually necessary to divide the lateral circumflex femoral vein in order to expose an adequate length of profunda femoris artery (Figure 2). On completing the anastomosis, the sartorius muscle, when returned to its normal position, covers the graft. Standard closure of the deep fascia and skin is then performed.

### Summary

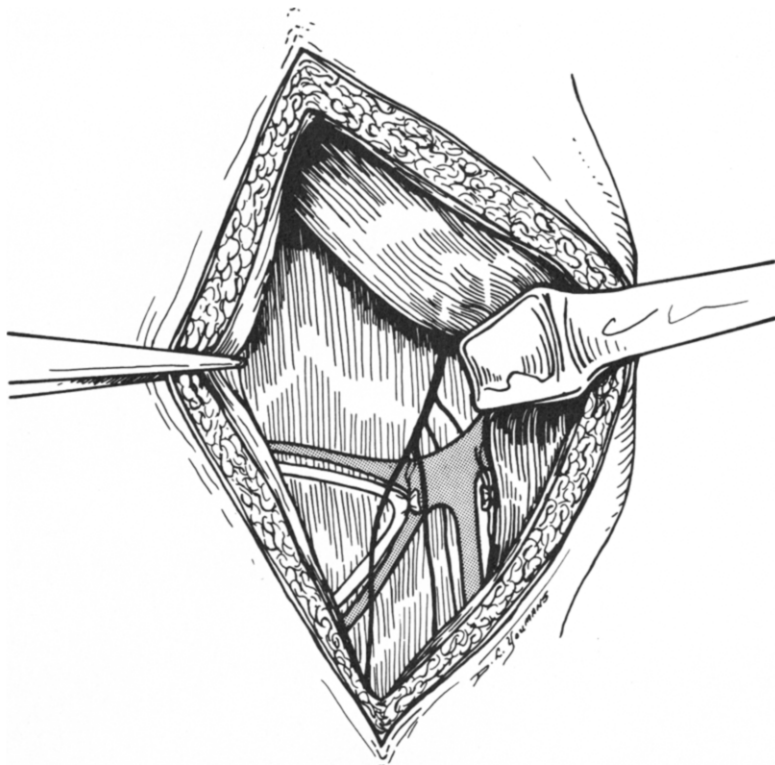
In five cases of prosthetic conduit infection in the groin we have successfully used this lateral approach to the deep femoral artery and encountered no sub-



*Figure 1. The profunda femoris artery lies deep to the sartorius muscle and can be approached by making an incision lateral to the sartorius muscle and drawing the muscle medially.*

From the Departments of Surgery, Albany Medical College and Veterans Administration Medical Center, Albany, New York 12208.

Requests for reprints should be addressed to John D. Corson, MD, Surgical Service, Veterans Administration Medical Center, Albany, New York 12208.



*Figure 2. The sartorius muscle is drawn medially to show the lateral circumflex vessels, branches of the femoral nerve, and the profunda femoris artery deep to the divided lateral circumflex vein.*

sequent sepsis in the new graft. In 18 other cases of severe groin scarring, this approach facilitated dissection and permitted limb revascularization using the profunda femoris artery as either an inflow source

or an outflow tract. We therefore recommend this technique for complicated secondary vascular reconstructions in the groin, where a direct approach would be both difficult and hazardous.