

CASE REPORT

Late small bowel obstruction after blunt abdominal trauma

D Maharaj, A Perry, M Ramdass, V Naraynsingh

Postgrad Med J 2003;79:57–58

Blunt abdominal trauma with intraperitoneal injury usually presents acutely. On rare occasions, such patients can present later on with features of small bowel obstruction due to stricture formation. It is thought that such a delayed stricture is due to subclinical bowel perforation, localised gut ischaemia, or injury to the mesenteric vasculature. This case demonstrates the mesenteric vascular injury theory to be the cause of the bowel stricture.

Blunt abdominal trauma producing intraperitoneal injury usually presents acutely, necessitating laparotomy for intestinal perforation or mesenteric vascular injury.¹ In the absence of shock and peritonism, patients with blunt abdominal injury may be treated conservatively. On rare occasions, such patients can present later on with features of small bowel obstruction.^{2,3} Delays in presentation between the initial insult to the abdomen and the obstructive episode have been documented to be as long as 26 years in the European literature.⁴

The exact pathophysiology is unclear, with three possible causes cited—subclinical small bowel perforation, localised bowel ischaemia, and mesenteric vascular injury.⁵ We report the case of a 22 year old man who presented with small bowel obstruction two years after blunt abdominal trauma. Laparotomy revealed distal ileal stenosis with vascular mesenteric injury. This case reinforces the mesenteric vascular injury theory as the cause of the bowel stricture.

CASE REPORT

A healthy 20 year old man presented to the General Hospital, Port-of-Spain, having been involved in a motor vehicle accident one hour beforehand. He was the driver of a car that smashed into the rear of a stationary vehicle at low velocity. He was wearing a lap and shoulder belt at the time.

Though he sustained blunt abdominal injury, bruising or the seatbelt sign were not evident. He was found to be stable with minimal abdominal tenderness. He was observed for a 24 hour period and subsequently discharged.

He was seen repeatedly in the outpatient clinic for vague colicky abdominal pains which he had not experienced before injury. No investigations were ordered. Two years after the initial injury he presented to the surgical service with vomiting and constipation. His abdomen was mildly tender and grossly distended with increased bowel sounds. Plain abdominal radiographs revealed small bowel distension involving the jejunum and ileum.

A laparotomy was performed and a stricture of the terminal ileum was observed. The adjacent mesentery was scarred and the mesenteric arterial pulsations were impalpable (fig 1). On table Doppler assessment revealed reduced biphasic arterial impulses within this segment of mesentery.

The stenosed segment of ileum was resected and an end to end anastomosis performed. The specimen was examined his-

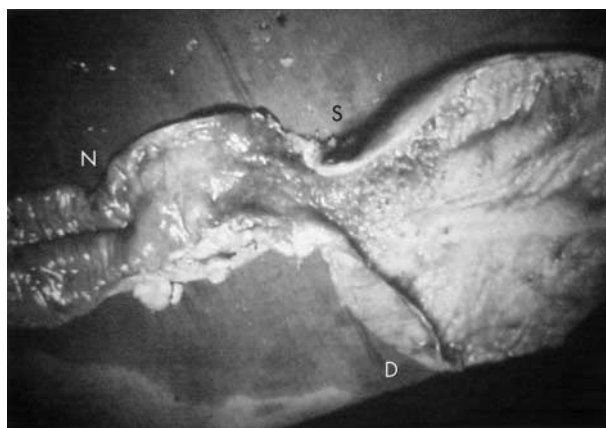


Figure 1 Stricture of the small bowel with scarring of the mesentery. From right to left: distended proximal small bowel (D), strictured segment (S), and normal small bowel (N).

tologically, revealing mucosal ulceration of the gut and degenerative infiltration of the mesenteric vessels.

The patient was discharged after an uneventful postoperative course, and has remained symptom-free after five years.

DISCUSSION

Delayed small bowel obstruction after blunt abdominal trauma is a rare clinical entity, with only a few anecdotal case reports described in the world literature.⁶ Some controversy exists about the exact cause of the intestinal stenosis.

It is thought that the fixed portions of the small bowel, namely, the terminal ileum and proximal jejunum, are prone to perforation during blunt abdominal trauma. A small subclinical perforation may seal off spontaneously producing a stricture due to scar formation.⁷ Welch and Anderson described such a phenomenon in a patient who sustained blunt abdominal trauma due to a seat belt injury two months before presentation.⁸ Such an explanation is indeed plausible, but is not found in the majority of cases.

Another mechanism for post-traumatic small bowel stricture formation is localised bowel ischaemia. Nielsen described the case of a 5 year old girl presenting with small bowel obstruction two weeks after sustaining blunt abdominal trauma in a car accident. Histological examination of the small bowel stricture revealed ulcer formation and fibrosis indicating ischaemic stenosis.⁹ It is more likely, however, for focal ischaemia of the gut to be secondary to a mesenteric insult rather than direct ischaemia of the bowel wall.¹⁰ It is the authors' view that it is far more likely for the vasculature of the mesentery to be injured by external forces as this structure is fixed retroperitoneally and is less elastic than bowel wall. Bowel is a hollow viscus and hence deforming forces are more likely to be dampened and dissipated.

Several reports on the subject have implicated mesenteric injury as the cause of the stricture formation.^{11–13} Mesenteric

Summary points

- Patients sustaining blunt abdominal trauma may present with delayed small bowel obstruction due to stricture formation.
- The possible causes of the small bowel stricture include: subclinical small bowel perforation, localised bowel ischaemia, and mesenteric vascular injury.
- This case demonstrates two points:
 1. Small bowel stricture formation is likely to be due to mesenteric vascular injury.
 2. This clinical entity should be borne in mind when faced with a patient presenting with small bowel obstruction after blunt abdominal trauma, even if the initial insult was months before.

tears or intramural haematomas have been found on close inspection of the specimens.¹⁴ Bryner *et al* described three patients with strictures due to mesenteric rents and subsequent devascularisation.¹⁵ Our case supports the mesenteric injury theory. At laparotomy, obvious mesenteric scarring was associated with the stricture formation; furthermore, impaired vascularity was confirmed by palpation and examination of audible Doppler signals.

Regardless of the pathophysiology of this complication of blunt abdominal trauma, the diagnosis of post-traumatic small bowel stricture should be suspected when a patient presents with features of bowel obstruction weeks, or even years, after sustaining abdominal injury. Plain abdominal films may confirm the diagnosis particularly during a bout of colicky pain. Unfortunately in this case the condition remained undiagnosed due to his vague presentation and the lack of clinical suspicion. In the unclear case, contrast enhanced computed tomography or angiography may reveal a mesenteric haematoma or mesenteric vessel occlusion respectively. With the incidence of blunt abdominal trauma due to seatbelt injuries on the upsurge,¹⁶ awareness of this interesting phenomenon cannot be overemphasised.

.....

Authors' affiliations

D Maharaj, A Perry, M Ramdass, V Naraynsingh, Department of Surgery, University of the West Indies, General Hospital, Port-of-Spain, Trinidad, West Indies

Correspondence to: Dr Maharaj; dalemaharaj@hotmail.com

Submitted 17 May 2002

Accepted 27 August 2002

REFERENCES

- 1 **Asbun HJ**, Irani H, Roe EJ, *et al*. Intra-abdominal seatbelt injury. *J Trauma* 1990;**30**:189-93.
- 2 **Law CH**, Brenneman FD, Rizoli SB, *et al*. Post-traumatic small-bowel stricture: a case report. *Can J Surg* 1996;**39**:57-8.
- 3 **Loberant N**, Szvalb S, Herskovits M, *et al*. Posttraumatic intestinal stenosis: radiographic and sonographic appearance. *Eur Radiol* 1997;**7**:524-6.
- 4 **Vanderschot PM**, Broos PL, Gruwez JA. Stenosis of the small bowel after blunt abdominal trauma. *Unfallchirurg* 1992;**95**:71-3.
- 5 **Lane TM**, Williams TG. Small bowel obstruction following blunt abdominal trauma. *Injury* 1998;**29**:484-5.
- 6 **Pohl MJ**, Cook WJ. Small-bowel stenosis after seat belt injury. *Med J Aust* 1980;ii:156.
- 7 **Allen JC**. Post-traumatic small bowel obstruction. *J R Army Med Corps* 1994;**140**:47-8.
- 8 **Welch GH**, Anderson JR. Small bowel stricture following abdominal trauma. *Postgrad Med J* 1985;**61**:1087-8.
- 9 **Nielsen RT**. Ischemic stenosis of the small intestine after blunt abdominal trauma. *Ugeskr Laeger* 1998;**160**:439-40.
- 10 **Loberant N**, Szvalb S, Herskovits M, *et al*. Posttraumatic intestinal stenosis: radiographic and sonographic appearance. *Eur Radiol* 1997;**7**:524-6.
- 11 **Tsushima Y**, Yamada S, Aoki J, *et al*. Ischaemic ileal stenosis following blunt abdominal trauma and demonstrated by CT. *Br J Radiol* 2001;**74**:277-9.
- 12 **De Backer AI**, De Schepper AM, Vaneerdeweg W, *et al*. Intestinal stenosis from mesenteric injury after blunt abdominal trauma. *Eur Radiol* 1999;**9**:1429-31.
- 13 **Isaacs P**, Rendall M, Hoskins EO, *et al*. Ischemic jejunal stenosis and blind loop syndrome after blunt abdominal trauma. *J Clin Gastroenterol* 1987;**9**:96-8.
- 14 **Bryner UM**, Longerbeam JK, Reeves CD. Posttraumatic ischemic stenosis of the small bowel. *Arch Surg* 1980;**115**:1039-41.
- 15 **Bartolozzi C**, Boutourline A. Delayed post-traumatic stenosis of the small bowel: report of a case. *Radiol Med (Torino)* 1980;**66**:409-13.
- 16 **Chandler CF**, Lane JS, Waxman KS. Seatbelt sign following blunt trauma is associated with increased incidence of abdominal injury. *Am Surg* 1997;**63**:885-8.