

See discussions, stats, and author profiles for this publication at: <https://www.researchgate.net/publication/308263810>

# FISH BONE PERFORATION OF SMALL BOWEL MIMICKING ACUTE APPENDICITIS

Article in International Journal of Research - GRANTHAALAYAH · July 2016

DOI: 10.5281/zenodo.58694

CITATION

1

READS

454

4 authors, including:



**Shariful Islam**

University of the West Indies, St. Augustine

112 PUBLICATIONS 104 CITATIONS

SEE PROFILE



**Patrick Harnarayan**

University of the West Indies, St. Augustine

84 PUBLICATIONS 183 CITATIONS

SEE PROFILE



**Vijay Naraynsingh**

Medical Associates

326 PUBLICATIONS 1,625 CITATIONS

SEE PROFILE

Some of the authors of this publication are also working on these related projects:



Reconstructive surgery [View project](#)



Non antibiotic management of acute uncomplicated diverticulitis [View project](#)



Science

## **FISH BONE PERFORATION OF SMALL BOWEL MIMICKING ACUTE APPENDICITIS**

**Dr. Shariful Islam <sup>\*1</sup>, Anthony Maughn <sup>2</sup>, Patrick Harnarayn <sup>3</sup>,  
Professor Vijay Naraynsingh <sup>4</sup>**

<sup>\*1,2</sup> Department of General Surgery, San Fernando Teaching Hospital, TRINIDAD AND TOBAGO

<sup>3,4</sup> Department of Clinical Surgical Sciences, University of the West Indies, St Augustine, TRINIDAD AND TOBAGO

DOI: 10.5281/zenodo.58694

### **ABSTRACT**

*Accidental ingestion of foreign bodies is a commonly encountered event in clinical practice. However, small bowel perforation due to a fish bone is a rare phenomenon. Often, the exact diagnosis is missed preoperatively and is revealed only at laparotomy. Delay in diagnosis and treatment can be associated with significant morbidity and mortality. We report a case of 54-year male who presented with right lower quadrant pain with nausea and vomiting. Clinically, Acute appendicitis was diagnosed. Computerized tomography (CT) of the abdomen confirmed pockets of free air in the right lower quadrant with fat streaking suggestive of perforated ileum. On exploratory laparotomy, the ileal perforation was confirmed secondary to a fish bone. Although rare, foreign body perforation of the small bowel should be entertained in the differential diagnosis in certain groups of patients presenting with acute abdomen.*

#### **Keywords:**

*Small bowel perforation, fish bone or foreign body perforation of small bowel.*

**Cite This Article:** Dr. Shariful Islam, Anthony Maughn, Patrick Harnarayn, and Professor Vijay Naraynsingh, “FISH BONE PERFORATION OF SMALL BOWEL MIMICKING ACUTE APPENDICITIS” International Journal of Research – Granthaalayah, Vol. 4, No. 7 (2016): 66-74.

### **1. INTRODUCTION**

Ingestion of a sharp foreign body (fish bone) is mostly accidental. Most of the swallowed foreign bodies are expelled out of the body in stool without causing any problem. Perforation due to fish bone ingestion can occur at any site along the gastro-intestinal (GI) tract [1]. In only 1% of patients, the foreign body perforates the distal ileum [2]. Preoperative diagnosis of fish bone induced perforation of small bowel is rarely made because the clinical presentation is non-specific and it can mimic a number of surgical conditions like appendicitis and diverticulitis. An

erect chest X-ray may show free gas under the diaphragm and abdominal X-ray often shows no specific findings as non-metallic objects are rarely visualised. Computerized tomography (CT) scan may identify the foreign body and its associated complications - micro-perforation, fistulisation or obstruction. Early intervention should be taken to prevent further morbidity and mortality.

## 2. THE CASE

A 63 year old diabetic male presented to the emergency department with 3-day history of right iliac fossa pain which worsened over the last 6 hours. The patient also had nausea, vomiting but no fever or diarrhoea. On examination, he was ill looking, with pink, moist mucous membranes. He had a pulse of 102/min but normotensive. He was markedly obese with a BMI of 40. There was guarding and rebound tenderness over the Mc Burney's point; the bowel sounds were hypoactive. Rectal examination was normal.

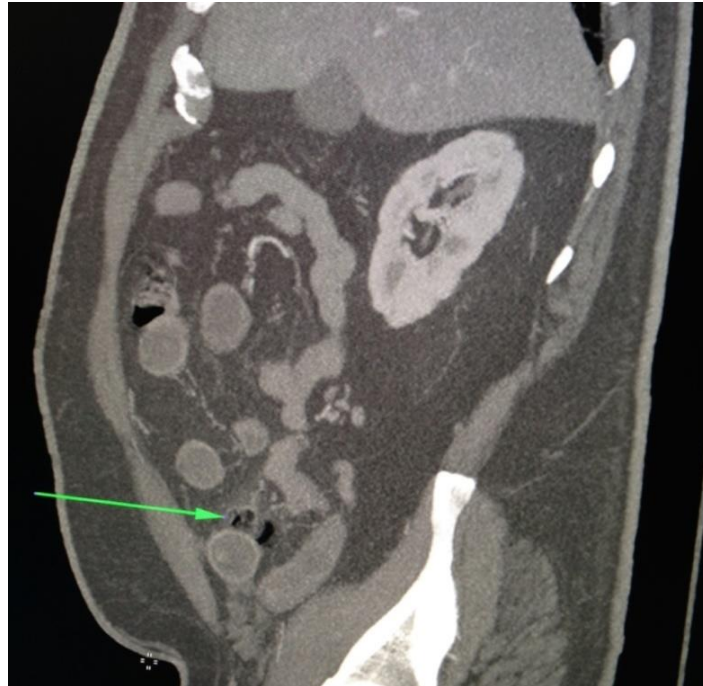
The white blood count was  $19 \times 10^3 / \mu\text{L}$  (reference: 4.0-11) and Hb was 13.8 g / dL.

Erect Chest X-ray revealed no free air under right diaphragm. Plain abdominal radiography showed localized ileus in the right lower quadrant.

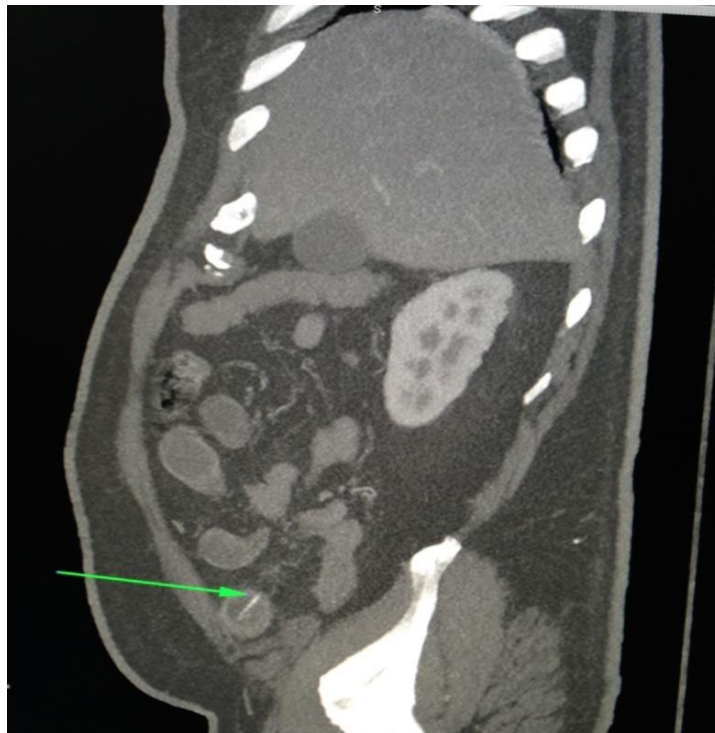Computerized tomography scan revealed a pocket of free air in right lower quadrant (fig. 1). The terminal ileum was moderately distended and there also was mild fat streaking. Of note a linear foreign body was noted to be penetrating out of the small bowel (fig. 2). The appendix was normal.

A clinical diagnosis of ruptured appendix was suspected. The patient was resuscitated and started on broad spectrum antibiotic.

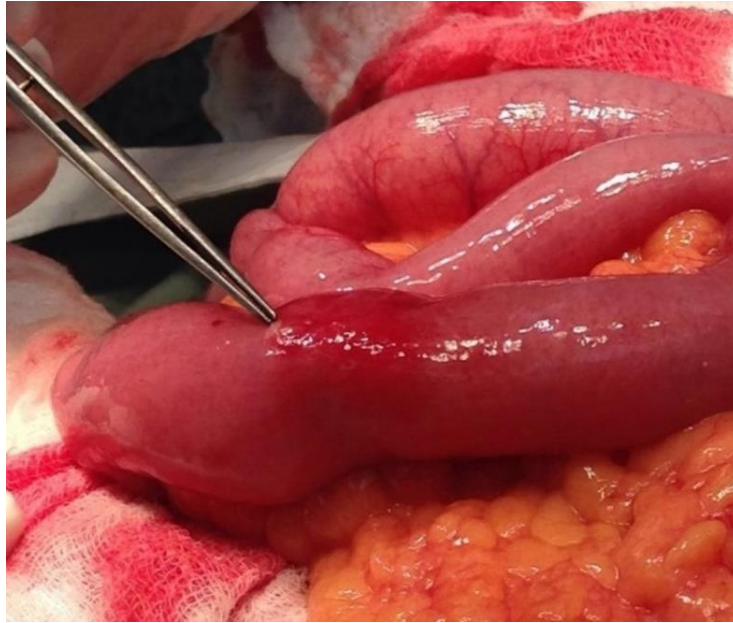
The patient was carried for emergency exploratory laparotomy. The abdomen was opened by midline incision. The localized collection of pus in right lower quadrant was sucked out. The terminal ileum was distended, edematous, and adjacent to a fish bone perforation 20 cm from the ileo-caecal valve (fig. 3). The foreign body was removed and it was noted to be a fish bone (fig. 4). The margins of the perforation were excised and primary closure was performed. The patient recovered well and was discharged on the 5th postoperative day. On interrogation the patient acknowledged that he incidentally swallowed a piece of fish bone 4days ago. At 6 months follow up our patient has no recurring abdominal symptoms and presently doing well.



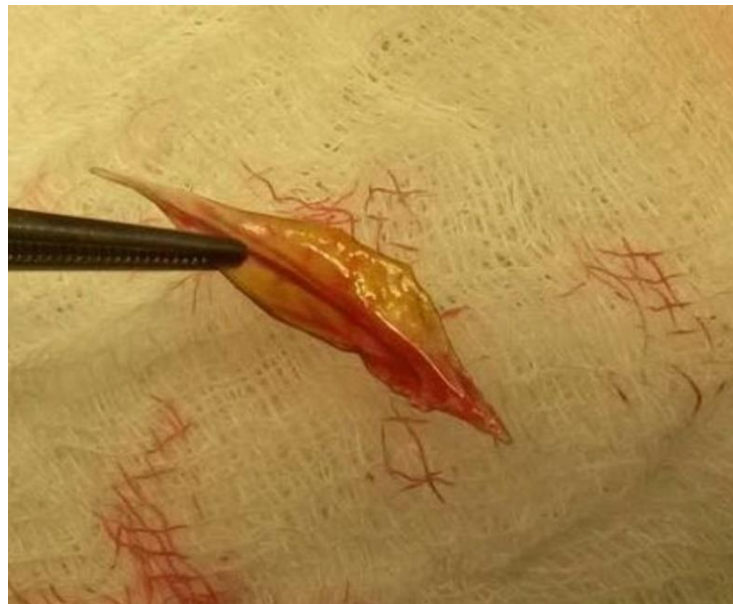**Figure 1:** CT scan of abdomen and pelvis showing pockets of free air in right iliac fossa



**Figure 2:** CT scan of abdomen and pelvis showing the presence of a hyper dense lesion within the lumen of the distended ileum



**Figure 3:** Intraoperative photo showing the perforation of the terminal ileum



**Figure 4:** Picture of the fish bone (after removal from the lumen of the ileum)

### 3. DISCUSSION

Foreign body (FB) ingestion is a common problem worldwide with an estimated incidence of 120 per million populations and it accounts almost 1500 deaths each year [3].

FB ingestion is seen in both adults and children. Toddlers are the most frequently affected [4]. Although rare in conscious and stable adults, it is fairly a common problem in psychiatric patients [3, 5, 6]. In normal adults foreign body ingestion is mostly accidental. The exact

aetiology in these groups is not well understood. Certain risk factors increase the chances of swallowing foreign bodies; these include advanced age, rushed, overeating, rapid eating habits as in our case, or a voracious appetite, defective tactile sensation of the palate, previous gastric surgery enhancing the passage of foreign bodies or causing stenosis and adhesions, achlorhydria where the foreign body passes unaltered from the stomach, and diverticula predisposing to impaction [3, 6, 7].

Intentional foreign body ingestion is commonly reported in certain adult populations. Velitchkov et al in his series of 542 patients from 1973 to 1993 from Bulgaria noted that 70% of the patients were jail inmates and more than 20% of them had psychiatric conditions [8].

The literature has documented different forms of ingested foreign bodies. Some of them are sharp and some blunt.

Among these, sharp objects i.e- fish bones [9, 10, 11], chicken bones [12, 13, 14, 15]. metallic rods and needles [12, 16], tooth picks [17], pins and needles remain the most common cause of gastro intestinal perforation [2]. Very rarely pens, metal wires, small trocar [18], spoon handle, nail clippers, nails, laundry pegs, dental prosthesis [19, 20, 21], batteries [22], injurious foreign agent [23], wireless capsule endoscopy [24, 25, 26], migrating biliary sent, gossybiopioma [27], schistosomia japonicum [28], unusual FB [29] may also cause gastro intestinal perforations. Several authors have documented that fish bone remains the most common cause of GI perforation [3, 6, 30]. However Pinero Madrona et al documented that chicken bone remains the most common cause of GI perforation in their population.

The most common location of GI perforation is in the angulated areas i.e-ileo-caecal valve or the recto-sigmoid junction; however, it can occur in any part of small bowel. The distal ileum remains the most common location (38.6%) of GI perforation [6, 31]. Occasionally foreign body perforation occurs in the duodeno-jejunal flexure, colonic flexures, hernial sac, appendix, Meckel's or colonic diverticulum and anal sphincter [32, 33]. In cases of sigmoid perforation, diverticulitis or unsuspected colon carcinoma have been reported as a secondary findings [15, 34]. Colorectal or colovesical fistulas have also been reported as being caused by ingested foreign bodies [19, 35]. In our case the perforation occurred approximately 20 cm proximal to the ileo-caecal valve.

In infants, foreign bodies 2 or 3 cm in length may become impacted in the duodenum, however in adults; objects longer than 5 cm can pass through the 'C' loop of the duodenum into the jejunum [12].

The clinical presentation is varied from un-seen passage per rectum to severe peritonitis following bowel perforation or acute bowel obstruction. Perforation of the stomach, duodenum or colon tends to have a delayed presentation compared to perforation of the small bowel [36]. Abdominal pain is the most frequently presenting symptom and is usually associated with nausea, vomiting, fever or diarrhoea. Different findings include localized abdominal abscess, inflammatory mass or omental pseudo-tumor, chronic or acute intestinal obstruction, enterovesical, colovesical or colorectal fistula, bleeding, renal or ureteral colic and endocarditis [3, 37, 38].

Foreign body perforation of small bowel presenting as right iliac fossa pain mimicking as an acute appendicitis is very rare. Perforations of the stomach and duodenum by needles can be silent [16]. The most common diagnosis of RIF pain in both male and female is acute appendicitis.

Several investigations can be used for determining foreign body perforation or obstruction in the gastrointestinal tract and each has its distinct advantages. Abdominal X-ray can demonstrate the metallic foreign body, localized ileus or bowel obstruction but may fail to detect nonmetallic objects like ours [39]. Abdominal ultrasound examination can be helpful in detecting any free fluid, localized abscess or any gynecological pathology but it is operator dependent and of limited value in obese patients. The non-radio opaque objects can be detected on USS, because of their background shadowing and high reflection rates [31]. Our patient was very obese hence USS of the abdomen and pelvis was not performed. The computerized tomography (CT) scan of abdomen remains the imaging modality of choice. It can demonstrate the non-metallic foreign body (fish bones), any perforation, fat streaking, localized abscess, intestinal obstruction or other pathology [31, 32, 34]. Multi detector CT offers the best possibility of reapplication with high resolution. It is currently accepted as the first line investigation in patients with acute abdomen and in determination of foreign bodies [37].

In some cases imaging findings can be nonspecific; however, the finding of a foreign body with extra-luminal pockets of free air or an associated mass in patients with clinical signs of peritonitis, mechanical bowel obstruction, or pneumo-peritoneum strongly suggests the diagnosis of foreign body perforation [12, 40]. Finally, endoscopic examination, especially in the upper gastrointestinal tract, can be useful in diagnosis and management of ingested foreign bodies. In our case abdominal CT with contrast agent revealed the perforation caused by the ingested fish bone with a linear lesion with hyper density surrounded by inflamed tissues.

The management of this patient depends on presentation. As perforation generally leads to an acute abdomen, the treatment of choice is surgery. However, the patient with localized tenderness without any temperature spikes or tachycardia and CT evidence of localized abscess, micro-perforation, fistula or ileus can often be managed conservatively with broad spectrum antibiotics along with percutaneous drainage, laparoscopic washout and drainage [9].

At laparotomy, if the perforation site is sealed off and not identifiable, simple suction of the abscess, wash out with placement of a drain is sufficient [9].

However, once the perforation site is identified, the exact nature of the surgery (i.e either excision of the margins with primary repair [11] or segmental resection and anastomosis [10] depends on the size of the perforation, degree of contamination, underlying condition of the bowel and judgement of the surgeon.

Although there are case reports of successful repair of the perforation with the primary repair like ours, most authors recommend segmental resection and anastomosis [11,10].

#### **4. CONCLUSION**

Although rare, foreign body perforation of the small bowel should be entertained in the differential diagnosis in all patients presenting with acute abdomen. History taking should include accidental ingestion of any foreign body in the past in order to consider this diagnosis. Emphasis should be given to early diagnosis and treatment to prevent minimise and mortality

#### **5. LEARNING POINTS**

- Fish bone perforation of small bowel is a rare occurrence.
- The diagnosis of fish bone perforation of the ileum can often be missed.
- However, it should be entertained in all high risk patients presenting with right lower quadrant pain
- A contrast CT scan should be obtained to pinpoint the diagnosis in these patients.
- Aggressive resuscitation and prompt treatment should be done to prevent further morbidity and mortality.

#### **6. ACKNOWLEDGEMENTS**

The authors acknowledge the contribution of Dr. Srinivas Dola, Registrar at the Department of Radiology, San Fernando General Hospital, Trinidad and Tobago for his contribution in reporting the CT scan of the abdomen and pelvis of this patient.

#### **7. CONFLICTS OF INTEREST**

The authors have declared no conflicts of interest

#### **8. AUTHOR'S DECLARATION**

The authors have nothing to disclose

#### **9. PATIENT'S CONSENT**

Patient consent was obtained for publication of this article

#### **10. REFERENCES**

- [1] E. Mc Canse, A. Kurchin, S.R. Hinshaw *Gastrointestinal foreign bodies Am J Surg*, 142 (1981), pp. 335–337
- [2] M.A. Pinero, J.A. Fernandez, P.M. Carrasco, R.J. Riguelme, P.P. Parrilla, *Intestinal perforation by foreign bodies Eur J Surg*, 166 (2000), pp. 307–309
- [3] Ayantunde AA and Oke T (2006), *A review of gastrointestinal foreign goodies; International Journal of Clinical Practice* 60(6) 735–9
- [4] Nagaraj HS and Sunil I (2005). *Multiple foreign body ingestion and ileal perforation, Paediatric Surgery International* 21(9) 718–20



- [5] Jo Nandi P and Ong GB (1978). *Foreign body in oesophagus: review of 2394 cases. British Journal of Surgery* 65 5–9
- [6] Goh BK, Chow PK, Quah HM, Ong HS, Eu KW, Ooi LL and Wong WK (2006). *Perforation of gastro-intestinal tract secondary to ingestion of foreign bodies, World Journal of Surgery* 30(3) 372–7
- [7] B. Coulier, M.H. Tancredi, A. Ramboux *Spiral CT and multi-detector-row CT diagnosis of perforation of the small intestine caused by ingested foreign bodies Eur Radiol*, 14 (2004), pp. 1918–1925
- [8] Velitchkov NG, Grigorov GI, Losanoff JE and Kjossev KT (1996); *Ingested foreign bodies of the gastrointestinal tract: retrospective analysis of 542 cases. World Journal of Surgery* 20(8) 1001–5
- [9] Alex M Almoudarisa, Andre Chowa, Sashin Kaneriaa, Zainab Jiyada, Dimitri J Hadjiminias, *Fish Bone Perforation Mimicking Acute Appendicitis, Journal of Medical Cases, ISSN 1923-4155 print, 1923-4163 online*
- [10] Sheng-Der Hsu, De-Chuan Chan, Yao-Chi Liu, *Small-bowel perforation caused by fish bone World J Gastroenterol* 2005;11(12):1884-1885, ISSN 1007-9327
- [11] Huseyin Pulata, Oktay Karakosea, Mehmet Fatih Benzinb, Seyma Benzinc, Recep Cetina, *Small bowel perforation due to fish bone: A case report, Turkish Journal of Emergency Medicine, Volume 15, Issue 3, September 2015, Pages 136–138, doi:10.1016/j.tjem.2015.11.008*
- [12] Khan AS and Ali U (2006). *Ingestion of metallic rods and needles; Journal of the College of Physicians and Surgeons Pakistan* 16(4) 305–6
- [13] Sandeep Joglekar, Iqbal Rajput, Sachin Kamat and Sarah Downey, *Sigmoid perforation caused by an ingested chicken bone presenting as right iliac fossa pain mimicking appendicitis: a case report Journal of Medical Case Reports*20093:7385 DOI: 10.4076/1752-1947-3-738
- [14] A Patloo, M Zaz, A Amin, R Bali, M Khan, M Khan. *Small-Bowel Perforation Caused By A Swallowed Chicken Bone – A Case Report. The Internet Journal of Surgery, 2012 Volume 28 Number 4*
- [15] Kimbrell FT Jr, Tepas JJ and Mullen JT (1975); *Chicken bone perforation of the sigmoid colon: a report of three cases. The American Surgeon* 41(12) 814-7
- [16] M. Hashmonai, T. Kaufman, A. Schramer *Silent perforations of the stomach and duodenum by needles Arch Surg*, 113 (1978), pp. 1406–1409
- [17] Cossavella D, Clerico G, Paino O and Pozzo M (1998); *Trompetto M. Intestinal perforation caused by tooth picks; Minerva Chirurgica* 53(3) 219–22
- [18] Oscar D. Almeida, John M. Val-Gallas, MD2, *Small Trocar Perforation of the Small Bowel: A Case Report JSLS. 1998 Jul-Sep; 2(3): 289–290.PMCID: PMC3015313*
- [19] Cleator IG and Christie J (1973); *An unusual case of swallowed dental plate and perforation of the sigmoid colon. British Journal of Surgery* 60(2) 163-5
- [20] M. Maleki, W.E. Evans; *Foreign body perforation of the intestinal tract; report of 12 cases and review of the literature Arch Surg*, 101 (1970), pp. 474–477
- [21] Peter Webster, A Peckham-Cooper, Mark Lansdown, *Small bowel perforation secondary to accidental dental plate ingestion International Journal of Surgery Case Report* 2(7):218-20
- [22] Arshad M. Malik, *Small bowel perforations due to deliberate ingestion of injurious foreign bodies- a personal experience, J Ayub Med Coll Abbottabad* 2008;20 (2)

- [23] R. Alagar Samy and R. Purushothaman, *A rare case of a small bowel perforations with multiple foreign bodies due to deliberate ingestion of injurious foreign bodies*, *Indian Journal of Medical Case Reports* 2014 Vol. 3 (4) October-December, pp. 90-94 ISSN: 2319-3832(Online)
- [24] Y. Yagmur, H. Ozturk *Distal ileal perforation secondary to ingested foreign bodies* *J Coll Physicians Surg Pak*, 19 (2009), pp. 452-453
- [25] S. Akbulut, B. Cakabay, C.A. Ozmen, A. Sezgin, M.M. Sevinc, *An unusual cause of ileal perforation: report of a case and literature review* *World J Gastroenterol*, 15 (2009), pp. 2672-2674
- [26] Dhavan A Parikh, Janak A Parikh, Gregory C Albers and Charles F Chandler, *Acute small bowel perforation after wireless capsule endoscopy in a patient with Crohn's disease: a case report*, *Cases Journal* 2009, 2:7607 doi: 10.4076/1757-1626-2-7607
- [27] Tahsin Colak, Tolga Olmez, Ozgur Turkmenoglu, and Ahmet Dag, *Small Bowel Perforation due to Gossypiboma Caused Acute Abdomen*, *Case Rep Surg*. 2013; 2013: 219354. doi: 10.1155/2013/219354, PMID: PMC3830857
- [28] Jin-Jian Xiang, Ben-Jing Cheng, Fu Tian, Mi Li, Xue-Feng Jiang, Hui-Chuan Zhao, Xiao-Miao Hu, Bao-Lai Xiao, Jian-Ping Xie, and Arpana Shrestha, *Perforation of small bowel caused by Schistosoma japonicum: A case report* *World J Gastroenterol*. 2015 Mar 7; 21(9): 2862-2864. doi: 10.3748/wjg.v21.i9.2862, PMID: PMC4351245
- [29] J.I. Rodríguez-Hermosa, N. Canete, E. Artigau, J. Girones, P. Planellas, A. Codina-Cazador, *Small bowel perforation by an unusual foreign body* *Rev Esp Enferm Dig*, 101 (2009), pp. 639-641
- [30] K.M. Chu, H.K. Choi, H.H. Tuen, S.Y. Law, F.J. Branicki, J. Wong *A prospective randomized trial comparing the use of the flexible gastroscope versus the bronchoscope in the management of foreign body ingestion* *Gastrointest Endosc*, 47 (1998), pp. 23-27
- [31] B. Coulier *Diagnostic ultrasonography of perforating foreign bodies of the digestive tract* *J Belge Radiol*, 80 (1997), pp. 1-5
- [32] B.K. Goh, Y.M. Tan, S.E. Lin, et al. *CT in the preoperative diagnosis of fish bone perforation of the gastrointestinal tract* *AJR Am J Roentgenol*, 187 (2006), pp. 710-714
- [33] Malcolm Fidler, *Foreign-body perforation of jejunal diverticulum* *British Journal of Surgery* 59(9):744-5 .August 1972 DOI: 10.1002/bjs.1800590918
- [34] Ali W and Khan M (2007), *Intestinal perforation due to an ingested foreign body*; *Journal of the College of Physicians and Surgeons Pakistan* 17(4) 234
- [35] Eldridge WW Jr (1961). *Foreign bodies in the gastrointestinal tract*; *JAMA* 178 665-7
- [36] Karamarkovic AR, Djuranovic SP, Popovic NP, Bumbasirevic VD, Sijaki AD, Ivan V. *Hepatic abscess secondary to a rosemary twig migrating from stomach into liver*. *World j Gastroenterol*. 2007; 13(4):5530-32
- [37] M. Takada, R. Kashiwagi, M. Sakane, F. Tabata, Y. Kuroda *3D-CT diagnosis for ingested foreign bodies* *Am J Emerg Med*, 18 (2000), pp. 192-193
- [38] L. Ginzburg, A.J. Beller *The clinical manifestations of non-metallic perforating intestinal foreign bodies* *Ann Surg*, 86 (1927), pp. 918-939
- [39] P. Taourel, N. Kessler, A. Lesnik, P.M. Blayac, L. Morcos, J. M. Bruel, *Non-Traumatic abdominal emergencies: imaging of acute intestinal obstruction*, *Eur Radiol*, 12 (2002), pp. 2151-2160
- [40] *American society for gastrointestinal Endoscopy* (2002), *Guidelines for ingested foreign bodies*; *Gastrointestinal Endoscopy* 55 802-6