
CASE REPORT

“Swiss-Roll” Operation for Giant Fibroadenomas

Vijay Naraynsingh, FRCS, Dale Maharaj, FRCS, and Rajendra Rampaul, MBBS

*Department of Surgery, University of the West Indies, General Hospital,
Port-of-Spain, Trinidad, West Indies*

■ **Abstract:** Giant fibroadenomas can produce breast deformity and should be excised. Several techniques have been discussed, including a sub-mammary incision, which often leave a disfiguring scar. We describe a new technique for removal of such large masses via a small cosmetic circumareolar incision. ■

Key Words: giant fibroadenomas, cosmetic surgery

Cosmesis is an important consideration when making breast incisions, especially in the young adult. Excision of giant fibroadenomas poses a significant surgical challenge and is generally performed through large submammary incisions (1), which may produce unacceptable scarring.

We present a simple new technique in which we removed giant fibroadenomas through a small circumareolar incision in five consecutive patients.

TECHNIQUE

A 4-cm semicircular circumareolar incision was made. Breast skin was mobilized over the lump, and

an incision was made down to the lump. The mass was mobilized using the index finger until it was completely free from surrounding breast tissue. The mass was then grasped using a towel clip and pulled up to the skin, and an oblique incision was made into the fibroadenoma (Fig. 1). This incised portion was rotated out of the incision, and the lump was progressively incised and rotated (Fig. 2) until the entire mass was rotated out of the incision in a “Swiss roll”-type fashion (Fig. 3).

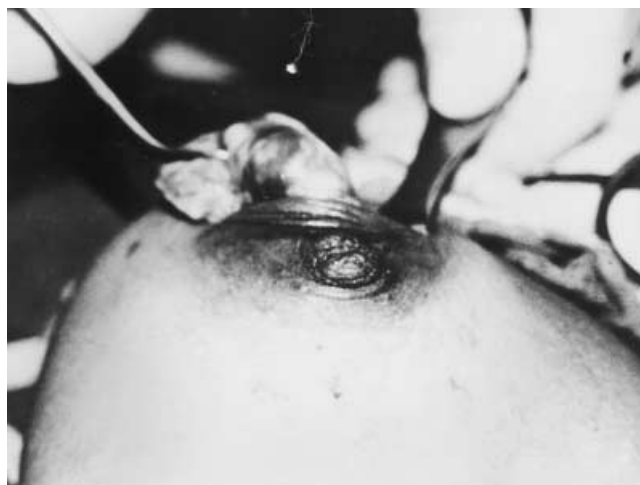

Figure 1. The fibroadenoma was grasped with a towel clip and brought to the wound. It was incised and rotated.

Address correspondence and reprint requests to: Vijay Naraynsingh, FRCS, Medical Associates, Cor. Albert & Abercromby Streets, St. Joseph, Trinidad, West Indies.

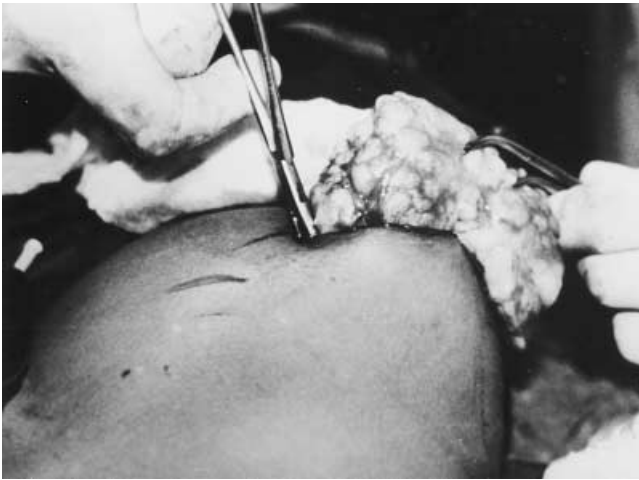


Figure 2. The lump was progressively incised and rotated out of the wound.

DISCUSSION

Giant fibroadenomas, which are greater than 5 cm (2), should be treated by local excision (3,4). This is a simple undertaking via a submammary incision. However, the scar produced is large and may not be hidden by the nonpendulous smaller breast. Healing of the submammary incision may be worse in Blacks, who are more prone to keloid and hypertrophic scarring; however, it is this group that is more prone to developing fibroadenomas. Furthermore, excision of upper quadrant tumors via the submammary incision is virtually impossible without hemorrhage and deformity of the breast.

One recognized alternative is to fragment the fibroadenoma in situ and then remove the fragments. However, there is the obvious risk of leaving pieces back. The Swiss-roll operation, if carried out correctly, prevents this complication and allows access to tumors in all quadrants of the breast.

Although some authors believe that circumareolar incisions could lead to extensive duct damage, careful planning of the incision could minimize this risk (5).

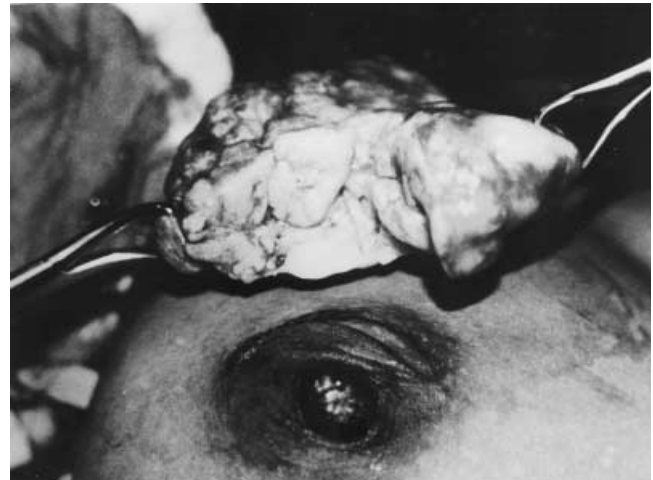

Figure 3. The mass was excised in toto and could be likened to a Swiss roll.

Indeed, in our experience, we have never seen this complication. Our Swiss-roll operation allows these large tumors to be removed through a cosmetically acceptable small incision.

REFERENCES

1. Alagaratnam TT, Ng WF, Leung EYF. Giant fibroadenomas of the breast in an oriental community. *J R Coll Surg Edinb* 1995;40:161-2.
2. Hughes LE. Fibroadenoma and related tumours. In: Hughes LE, Mansel RE, Webster DJT, eds. *Benign Disorders and Diseases of the Breast*. London: Balliere Tindall, 1989: 66-9.
3. Nanbiar R, Kannan Kutty M. Giant fibro-adenoma (cystosarcoma phyllodes) in adolescent females: a clinic pathologic study. *Br J Surg* 1974;61:113-7.
4. Amerson JR. Cystosarcoma phyllodes in adolescent females: a report of seven cases. *Ann Surg* 1970;171:849-56.
5. Williamson M, Lyons K, Hughes L. Multiple fibroadenomas of the breast: a problem of uncertain incidence and management. *Ann R Coll Surg Engl* 1993;75:161-3.